

Neurology®

Table of Contents

Volume 85, Number 9, September 1, 2015
Neurology.org

THE MOST WIDELY READ AND HIGHLY CITED PEER-REVIEWED
NEUROLOGY JOURNAL



IN FOCUS

- 745 Spotlight on the September 1 Issue
- 755 This Week's *Neurology*® Podcast

EDITORIALS

- 746 Ultrasound in neurolymphomatosis: The rise of the machines
F.O. Walker and M.S. Cartwright
- 748 Gene sleuthing in pyridoxine-dependent epilepsy
S. Weckhuysen and P.L. Pearl
- 750 Is dominantly inherited Alzheimer disease a clone of sporadic Alzheimer disease?
D.S. Knopman

ARTICLES

- 752 Role of combined B-mode and Doppler sonography in evaluating neurolymphomatosis
J. Vijayan, Y.C. Chan, A. Therimadasamy, and E.P. Wilder-Smith
  Editorial, p. 746
- 756 Intragenic deletions of *ALDH7A1* in pyridoxine-dependent epilepsy caused by *Alu-Alu* recombination
H.C. Mefford, M. Zemel, E. Geraghty, J. Cook, P.T. Clayton, K. Paul, B. Plecko, P.B. Mills, D.R. Nordli, Jr, and S.M. Gospe, Jr
Editorial, p. 748
- 763 Pediatric cavernous sinus thrombosis: A case series and review of the literature
D.M. Smith, A. Vossough, G.A. Vorona, L.A. Beslow, R.N. Ichord, and D.J. Licht

- 770 Natural course of total mismatch and predictors for tissue infarction
B. Hotter, A.-C. Ostwaldt, A. Levichev-Connolly, M. Rozanski, H.J. Audebert, and J.B. Fiebach
- 776 Cognitive performance and poor long-term functional outcome after young stroke
N.E. Synhaeve, P. Schaapsmeeders, R.M. Arntz, N.A.M. Maaijwee, L.C.A. Rutten-Jacobs, H.C. Schoonderwaldt, L.D.A. Dorresteyn, P.L.M. de Kort, E.J. van Dijk, R.P.C. Kessels, and F.-E. de Leeuw
- 783 Executive function, but not memory, associates with incident coronary heart disease and stroke
S. Rostamian, M.A. van Buchem, R.G.J. Westendorp, J.W. Jukema, S.P. Mooijaart, B. Sabayan, and A.J.M. de Craen
- 790 Cerebral amyloidosis associated with cognitive decline in autosomal dominant Alzheimer disease
F. Wang, B.A. Gordon, D.C. Ryman, S. Ma, C. Xiong, J. Hassenstab, A. Goate, A.M. Fagan, N.J. Cairns, D.S. Marcus, E. McDade, J.M. Ringman, N.R. Graff-Radford, B. Ghetti, M.R. Farlow, R. Sperling, S. Salloway, P.R. Schofield, C.L. Masters, R.N. Martins, M.N. Rossor, M. Jucker, A. Danek, S. Förster, C.A.S. Lane, J.C. Morris, T.L.S. Benzinger, R.J. Bateman, and the Dominantly Inherited Alzheimer Network
Editorial, p. 750
- 799 Risk factors for poor visual outcome in patients with idiopathic intracranial hypertension
M. Wall, J. Falardeau, W.A. Fletcher, R.J. Granadier, B.L. Lam, R.A. Longmuir, A.D. Patel, B.B. Bruce, H. He, and M.P. McDermott, for the NORDIC Idiopathic Intracranial Hypertension Study Group

- 806 Effects of education on aging-related cortical thinning among cognitively normal individuals
J.P. Kim, S.W. Seo, H.Y. Shin, B.S. Ye, J.-J. Yang, C. Kim, M. Kang, S. Jeon, H.J. Kim, H. Cho, J.-H. Kim, J.-M. Lee, S.T. Kim, D.L. Na, and E. Guallar
- 813 N-terminal pro-brain natriuretic peptide and abnormal brain aging: The AGES-Reykjavik Study
B. Sabayan, M.A. van Buchem, A.J.M. de Craen, S. Sigurdsson, Q. Zhang, T.B. Harris, V. Gudnason, A.E. Arai, and L.J. Launer

SPECIAL ARTICLE

- 821 Development of the Standards of Reporting of Neurological Disorders (STROND) checklist: A guideline for the reporting of incidence and prevalence studies in neuroepidemiology
D.A. Bennett, C. Brayne, V.L. Feigin, S. Barker-Collo, M. Brainin, D. Davis, V. Gallo, N. Jetté, A. Karch, J.F. Kurtzke, P.M. Lavados, G. Logroscino, G. Nagel, P.-M. Preux, P.M. Rothwell, and L.W. Svenson

CONTINUED

Neurology®

Table of Contents

continued



CLINICAL/SCIENTIFIC NOTES

- 829 CNS neutrophilic vasculitis in neuro-Sweet disease
R. Charlson, I. Kister, D. Kaminetzky, M. Shvartsbeyn, S.A. Meehan, and I. Mikolaenko

NEUROIMAGES

- 831 Severe MCA stroke without MCA occlusion? Thrombectomy uncovers accessory middle cerebral artery
A. Bayer-Karpinska, J. Lutz, T. Birnbaum, M. Dieterich, and F.A. Wollenweber

VIDEO NEUROIMAGES

- 833 Reversible frontotemporal brain sagging syndrome
C.F. Slattery, I.B. Malone, S.L. Clegg, J.D. Warren, and N.C. Fox



RESIDENT & FELLOW SECTION

- e69 Clinical Reasoning: Vanishing tumor: A 7-year puzzle solved
C.M. Kelly, S. O'Dowd, C. Drake, L. McCarthy, N. Bermingham, N. Fanning, S.S. O'Sullivan, and S. O'Reilly
- e74 Clinical Reasoning: A 27-year-old man with rapidly progressive coma
J.M. Wong, M. Chandra, R. VanDeBogart, B. Lu, and A.H. Yee

WRITECLICK® EDITOR'S CHOICE

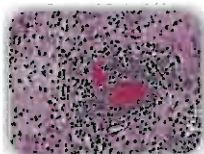
- 834 Colonic mucosal α -synuclein lacks specificity as a biomarker for Parkinson disease
C. Ruffmann, L. Parkkinen, J.M. Woulfe, M.T. Gray, D.G. Munoz; Author Response: N.P. Visarji, A.E. Lang, L-N. Hazrai

DEPARTMENT

In the Next Issue of *Neurology*®

Podcast at Neurology.org CME Video Patient Page LOE classification LOE recommendation

Find us on Facebook tinyurl.com/neurologyfan twitter twitter.com/GreenJournal



Cover image: Brain biopsy with diffuse inflammatory infiltrates with marked vasculitis composed predominantly of neutrophils in a patient with neuro-Sweet disease. See page 829.

Look for **Publish Ahead of Print** articles and editorials under the Ahead of Print tab at Neurology.org



Neurology® Online CME Program

Earn CME while reading *Neurology*. This program is available only to online *Neurology* subscribers. Simply read the articles marked CME, go to www.neurology.org, and click on CME. This will provide all of the information necessary to get started. The American Academy of Neurology (AAN) is accredited by the Accreditation Council for Continuing Medical Education (ACCME) to sponsor continuing medical education for physicians. *Neurology* is planned and produced in accordance with the ACCME Essentials. For more information, contact AAN Member Services at 800-879-1960.