

# Neurology<sup>®</sup>

## Table of Contents

Volume 85, Number 7, August 18, 2015  
Neurology.org

THE MOST WIDELY READ AND HIGHLY CITED PEER-REVIEWED  
NEUROLOGY JOURNAL



### IN FOCUS

- 559 Spotlight on the August 18 Issue  
645 This Week's *Neurology*<sup>®</sup> Podcast

### EDITORIALS

- 560 Should we train respiratory muscles after stroke?  
*S.T. Kulnik*
- 562 Dual antiplatelet therapy for TIA reduces subsequent disability: A CHANCE to improve outcomes?  
*Y.J. Alderazi*

### ARTICLES

- 564 Inspiratory and expiratory muscle training in subacute stroke: A randomized clinical trial  
*M. Messaggi-Sartor, A. Guillen-Solà, M. Depolo, E. Duarte, D.A. Rodríguez, M.-C. Barrera, E. Barreiro, F. Escalada, M. Orozco-Levi, and E. Marco*  
▲ Editorial, p. 580

- 573 Effect of clopidogrel with aspirin on functional outcome in TIA or minor stroke: CHANCE substudy  
*X. Wang, X. Zhao, S.C. Johnston, Y. Xian, B. Hu, C. Wang, D. Wang, L. Liu, H. Li, J. Fang, X. Meng, A. Wang, Y. Wang, and Y. Wang, for the CHANCE investigators*  
▲ Editorial, p. 582

- 580 Antiepileptic drugs and intrauterine death: A prospective observational study from EURAP  
*T. Tomson, D. Battino, E. Bonizzoni, J.J. Craig, D. Lindhout, E. Perucca, A. Sabers, S.V. Thomas, and F. Vajda, for the EURAP Study Group*  
▲

- 587 Comment: Stillbirths and spontaneous abortions in women with epilepsy on AEDs  
*N. Jetté*

- 589 Focal seizure symptoms in idiopathic generalized epilepsies  
*U. Seneviratne, J.J. Woo, R.C. Boston, M. Cook, and W. D'Souza*

- 594 Comment: Be careful what you ask when interviewing patients with epilepsy  
*J.C. Henry*
- 596 Effect of vaccinations on seizure risk and disease course in Dravet syndrome  
*N.E. Verbeek, N.A.T. van der Maas, A.C.M. Sonsma, E. Ippel, P.E. Vermeer-de Bondt, E. Hagebeuk, F.E. Jansen, H.H. Geesink, K.P. Braun, A. de Louw, P.B. Augustijn, R.F. Neuteboom, J.H. Schieving, H. Stroink, R.J. Vermeulen, J. Nicolai, O.F. Brouwer, M. van Kempen, C.G.F. de Kovel, J.M. Kemmeren, B.P.C. Koeleman, N.V. Knoers, D. Lindhout, W.B. Gunning, and E.H. Brilstra*
- 604 MRI in assessing children with learning disability, focal findings, and reduced automaticity  
*D.K. Urion, H.V. Huff, and M.P. Carullo*
- 610 Retinal pathology in Susac syndrome detected by spectral-domain optical coherence tomography  
*M. Ringelstein, P. Albrecht, I. Kleffner, B. Bühn, J. Harmel, A.-K. Müller, D. Finis, R. Guthoff, R. Bergholz, T. Duning, M. Krämer, F. Paul, A. Brandt, T. Oberwahrenbrock, J. Mikolajczak, B. Wildemann, S. Jarius, H.-P. Hartung, O. Aktas, and J. Dörr*
- 619 Cost-effectiveness of shared medical appointments for neuromuscular patients  
*F.M. Seesing, H.J. Groenewoud, G. Drost, B.G.M. van Engelen, and G.J. van der Wilt*  
▲
- 626 Amyloid precursor protein metabolism and inflammation markers in preclinical Alzheimer disease  
*D. Alcolea, P. Martínez-Lage, P. Sánchez-Juan, J. Olazarán, C. Antúnez, A. Izagirre, M. Ecay-Torres, A. Estanga, M. Clerigué, M.C. Guisasaola, D. Sánchez Ruiz, J. Marín Muñoz, M. Calero, R. Blesa, J. Clarimón, M. Carmona-Iragui, E. Morenas-Rodríguez, E. Rodríguez-Rodríguez, J.L. Vázquez Higuera, J. Fortea, and A. Lleó*

CONTINUED

# Neurology<sup>®</sup>

## Table of Contents

*continued*



### CLINICAL IMPLICATIONS OF NEUROSCIENCE RESEARCH

- 634 The autophagy-lysosomal pathway:  
General concepts and clinical implications  
*D.L. Kenney and E.E. Benarroch*

### VIEWS & REVIEWS

- 646 Opioids for chronic noncancer pain: To  
prescribe or not to prescribe—What is the  
question?  
*S.E. Nadeau*



- 650 Comment: Prescription opioids—Misused or  
misunderstood?  
*J.C.M. Brust*

### CLINICAL/SCIENTIFIC NOTES

- 652 Diffuse leukoencephalopathy with spheroids  
presenting as primary progressive  
aphasia  
*C. Oboudiyat, E.H. Bigio, B. Bonakdarpour,  
M.C. Baker, R. Rademakers, S. Weintraub, and  
M.-M. Mesulam*

### VIDEO NEUROIMAGES

- 654 Axial myoclonus after ischemic stroke  
*P.N. Alves, M. de Carvalho, R. Peralta, R. Gerales,  
A.C. Fonseca, and T. Pinho e Melo*



### RESIDENT & FELLOW SECTION

- e57 Clinical Reasoning: Worsening neurologic symptoms  
in a brain tumor patient  
*G. Faivre, E. Pentsova, A. Demopoulos, S. Taillibert,  
M. Rosenblum, and A. Omuro*

### WRITECLICK<sup>®</sup> EDITOR'S CHOICE

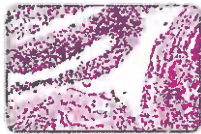
- 655 Teaching NeuroImages: The lentiform fork sign: An MRI  
pattern of metformin-associated encephalopathy  
*C. Kaiwar; Author Response: G.C. Fernandes,  
C.R.M. Rieder, L. Vedolin, L. Campos, T. Koltermann*
- 655 Vigabatrin retinal toxicity in children with infantile  
spasms: An observational cohort study  
*J.D. Akula; Author Response: C.A. Westall, T. Wright*

### DEPARTMENT

In the Next Issue of *Neurology*<sup>®</sup>

Podcast at [Neurology.org](http://Neurology.org) CME Video Patient Page LOE classification LOE recommendation

[Find us on Facebook](https://www.facebook.com/Neurologyfan) [tinyurl.com/neurologyfan](http://tinyurl.com/neurologyfan) [twitter.com/GreenJournal](https://twitter.com/GreenJournal)



**Cover image:** Autopsy revealed extensive leptomeningeal spread of glioma, which coated the spinal cord and engulfed nerve roots, contrasting with unremarkable imaging. See page e57.

Look for **Publish Ahead of Print** articles and editorials under the Ahead of Print tab at [Neurology.org](http://Neurology.org)