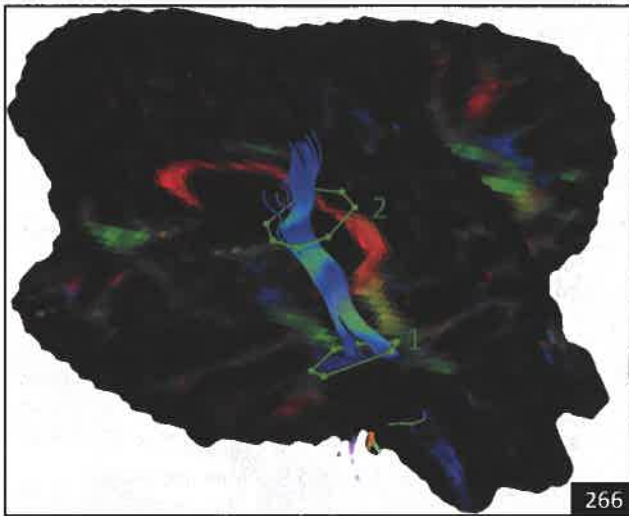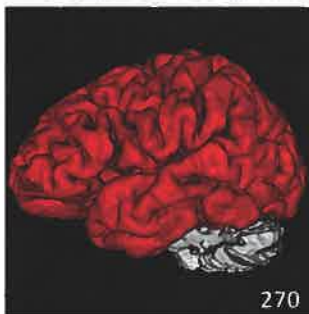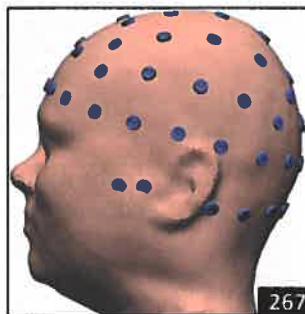


266



270



267

Select figures listed on the Table of Contents only appear within the full-length articles online.

In Focus

- 251 **Spotlight on the February 5 issue**
- 252 **This Week's *Neurology*® Podcast**

Editorials

- 253 **Optical coherence tomography for diagnosing optic neuritis: Are we there yet?**
S. Saidha and R.T. Naismith
- 255 **Upper motor neuron assessment and early diagnosis in ALS: Getting it right the first time**
D. Lacomis and C. Gooch
- 257 **Reducing disparity in neurologic care: What can we do?**
H. Moawad and C. Flippen II

- 259 **Patient-reported outcomes for subarachnoid hemorrhage: Capturing the patients' perspective**
G.M. Turner and J. Mant

Articles: Short Format

Full articles at Neurology.org/N

- 262 **Optical coherence tomography is highly sensitive in detecting prior optic neuritis**
S.C. Xu, R.H. Kardon, J.A. Leavitt, E.P. Flanagan, S.J. Pittock, and J.J. Chen
 - ➔ Editorial, p. 253
 - ➔ Class of Evidence
- 263 **Amyotrophic lateral sclerosis diagnostic index: Toward a personalized diagnosis of ALS**
N. Geevasinga, J. Howells, P. Menon, M. van den Bos, K. Shibuya, J.M. Matamala, S.B. Park, K. Byth, M.C. Kiernan, and S. Vucic
 - ➔ Editorial, p. 255
 - ➔ Class of Evidence
- 264 **Refining the spinobulbar muscular atrophy phenotype by quantitative MRI and clinical assessments**
J.R. Dahlqvist, S.T. Oestergaard, N.S. Poulsen, C. Thomsen, and J. Vissing
- 265 **Recurrent stroke in midlife is associated with not having a primary care physician**
R.J. Lank, L.D. Lisabeth, B.N. Sánchez, D.B. Zahuranec, K.A. Kerber, L.E. Skolarus, J.F. Burke, D.A. Levine, E. Case, D.L. Brown, and L.B. Morgenstern
 - ➔ CME Course
- 266 **Selective atrophy of the connected deepest cortical layers following small subcortical infarct**
E. Lotan, I. Tavor, D. Barazany, S. Ben-Amity, C. Hoffmann, G. Tsarfaty, Y. Assaf, and D. Tanne
- 267 **Electromagnetic source imaging in presurgical workup of patients with epilepsy: A prospective study**
L. Duez, H. Tankisi, P.O. Hansen, P. Sidenius, A. Sabers, L.H. Pinborg, M. Fabricius, G. Rásonyi, G. Rubboli, B. Pedersen, A.-M. Leffers, P. Uldall, B. Jespersen, J. Brennum, O.M. Henriksen, A. Fuglsang-Frederiksen, and S. Beniczky
 - ➔ CME Course
 - ➔ Open Access Article
 - ➔ Class of Evidence
- 268 **Leukoencephalopathy due to variants in *GFPT1*-associated congenital myasthenic syndrome**
G. Helman, S. Sharma, J. Crawford, B. Patra, P. Jain, S.J. Bent, J.A. Urtizberea, R.K. Saran, R.J. Taft, M.S. van der Knaap, and C. Simons
- 269 **Association of body mass index and waist-to-hip ratio with brain structure: UK Biobank study**
M. Hamer and G.D. Batty

➔ Ahead of Print Articles and Editorials

NPub.org/aheadofprint

Continued

270 **Associations between tau, A β , and cortical thickness with cognition in Alzheimer disease**

R. Ossenkoppele, R. Smith, T. Ohlsson, O. Strandberg, N. Mattsson, P.S. Insel, S. Palmqvist, and O. Hansson

Open Access Article

271 **Electrically induced verbal perseveration: A striatal deafferentation model**

E. Mandonnet, G. Herbet, S. Moritz-Gasser, I. Poisson, F. Rheault, and H. Duffau

What's Happening

272 **What's happening in *Neurology****

273 **What's happening in Innovations in Care Delivery**

Views & Reviews

274 **Reducing neurodisparity: Recommendations of the 2017 AAN Diversity Leadership Program**

E.T. Marulanda-Londoño, M.W. Bell, O.A. Hope, R.O. Leacock, C.B. O'Carroll, J. Posas III, N.P. Stover, R. Young, and R. Hamilton

📌 Editorial, p. 257 🎧 Podcast

281 **Do patient-reported outcome measures for SAH include patient, family, and caregiver priorities?: A scoping review**

V. Saigle, S. Asad, J. Presseau, M. Chassé, L. McIntyre, and S.W. English

📌 Editorial, p. 259

Clinical/Scientific Notes

296 **Simultaneous CMV and *Listeria* infection following alemtuzumab treatment for multiple sclerosis**

A. Pappolla, L. Midaglia, C.P. Boix Rodríguez, A.A. Puig, M. Lung, I.R. Camps, J. Castillo, P. Mulero, A. Vidal-Jordana, G. Arrambide, B. Rodríguez-Acevedo, J. Sastre-Garriga, J. Río, M. Comabella, I. Galán, M. Tintoré, and X. Montalbán

Resident & Fellow Section

299 **Pearls & Oysters: Diagnosis and monitoring of elevated intracranial pressure through ultrasound of the optic nerve**

J. Bar, J. Rosenberg, W. Chan, and N. Panebianco

e622 **Clinical Reasoning: Leg weakness and stiffness at the emergency room**

K. af Edholm, C. Lidman, S. Andersson, G. Solders, and M. Paucar

📺 Video

e626 **Teaching NeuroImages: Acute stroke captured on EEG in the ICU: Visual and quantitative analysis**

B.K. Kamitaki, B. Tu, A.S. Reynolds, and C.A. Schevon

e628 **Teaching NeuroImages: An imaging clue for treatable early childhood-onset dystonia: Manganism**

H. Padmanabha, S. Krishnamurthy, G.G. Sharath Kumar, I. Chikkanayakana, A. Sethuraman, and T. Mathew

Disputes & Debates: Editors' Choice

302 **Editors' note: Video NeuroImages: Paraneoplastic spinal myoclonus associated with Caspr2 antibodies**

J.E. Siegler III and S. Galetta

302 **Reader response: Video NeuroImages: Paraneoplastic spinal myoclonus associated with Caspr2 antibodies**

P.W. Tipton, J.A. van Gerpen, and R. Chen

303 **Author response: Video NeuroImages: Paraneoplastic spinal myoclonus associated with Caspr2 antibodies**

H. Hines, N.M. Murray, S. Ahmad, S. Jaradeh, and C.A. Gold

304 **Reader response: Video NeuroImages: Paraneoplastic spinal myoclonus associated with Caspr2 antibodies**

Philip W. Tipton, Jay A. van Gerpen, and Robert Chen

Correction

304 **Brain death, the determination of brain death, and member guidance for brain death accommodation requests: AAN position statement**

Department

In the Next Issue of *Neurology**



📺 **Cover image**

Ultrasound of the optic nerve measuring elevated intracranial pressure. Colorized by Cindy Abair, *Neurology* Senior Graphics Editor.

See page 299