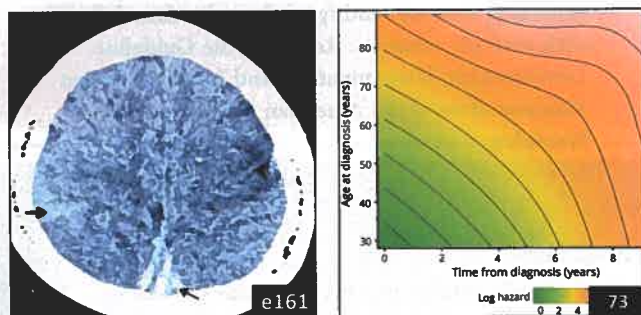

Select figures listed on the Table of Contents only appear within the full-length articles online.

Articles: Short Format

Full articles at Neurology.org/N

- 67 **Long-term treatment effect in cerebrotendinous xanthomatosis depends on age at treatment start**
B.M.L. Stelten, H.H. Huidekoper, B.P.C. van de Warrenburg, E.H. Brillstra, C.E.M. Hollak, H.R. Haak, L.A.J. Kluijtmans, R.A. Wevers, and A. Verrips
CME Course Editorial, p. 61
- 68 **SYNGAP1 encephalopathy: A distinctive generalized developmental and epileptic encephalopathy**
D.R.M. Vlaskamp, B.J. Shaw, R. Burgess, D. Mei, M. Montomoli, H. Xie, C.T. Myers, M.F. Bennett, W. XiangWei, D. Williams, S.M. Maas, A.S. Brooks, G.M.S. Mancini, I.M.B.H. van de Laar, J.M. van Hagen, T.L. Ware, R.I. Webster, S. Malone, S.F. Berkovic, R.M. Kalnins, F. Sicca, G.C. Korenke, C.M.A. van Ravenswaaij-Arts, M.S. Hildebrand, H.C. Mefford, Y. Jiang, R. Guerrini, and I.E. Scheffer
Editorial, p. 63 Open Access Article Video
- 69 **Spectrum and time course of epilepsy and the associated cognitive decline in MECP2 duplication syndrome**
D. Marafi, B. Suter, R. Schultz, D. Glaze, V.N. Pavlik, and A.M. Goldman
- 70 **Development and validation of a score to detect paroxysmal atrial fibrillation after stroke**
T. Uphaus, M. Weber-Krüger, M. Grond, G. Toenges, A. Jahn-Eimermacher, M. Jauss, P. Kirchhof, R. Wachter, and K. Gröschel
Editorial, p. 65 Podcast Class of Evidence
- 71 **Brain networks' functional connectivity separates aphasic deficits in stroke**
A. Baldassarre, N.V. Metcalfe, G.L. Shulman, and M. Corbetta
- 72 **Tau imaging detects distinctive distribution of tau pathology in ALS/PDC on the Kii Peninsula**
H. Shinotoh, H. Shimada, Y. Kokubo, K. Tagai, F. Niwa, S. Kitamura, H. Endo, M. Ono, Y. Kimura, S. Hirano, M. Mimuro, M. Ichise, N. Sahara, M.-R. Zhang, T. Suhara, and M. Higuchi
Open Access Article
- 73 **Age and time course of long-term motor and nonmotor complications in Parkinson disease**
S. Prange, T. Danaila, C. Laurencin, C. Caire, E. Metereau, H. Merle, E. Broussolle, D. Maucort-Boulch, and S. Thobois

In Focus

- 59 **Spotlight on the January 8 issue**
- 60 **This Week's Neurology® Podcast**

Editorials

- 61 **Cerebrotendinous xanthomatosis: The rare "treatable" disease you never consider**
G.V. Raymond and R. Schiffrmann
- 63 **A synaptic protein defect associated with reflex seizure disorder**
P. Striano and P. Huppke
- 65 **ECG monitoring after acute ischemic stroke: Does patient selection matter?**
M. Katan and S.A. Lubitz

What's Happening

- 74 **What's happening in Neurology® Clinical Practice**
- 75 **What's happening in Innovations in Care Delivery**

Contemporary Issues

- 76 **Neurology residency training in 2017: A survey of preparation, perspectives, and plans**
A. Mahajan, C. Cahill, E. Scharf, S. Gupta, S. Ahrens, E. Joe, and L. Schneider

Ahead of Print Articles and Editorials

NPub.org/aheadofprint

Continued

Views & Reviews**84 Translating the biology of aging into novel therapeutics for Alzheimer disease**

Y. Hara, N. McKeegan, and H.M. Fillit

Open Access

Clinical/Scientific Notes**94 Paroxysmal dyskinesias with drowsiness and thalamic lesions in GABA transaminase deficiency**

H. Morales-Briceño, F.C.F. Chang, C. Wong, A. Mallawaarachchi, N. Wolfe, R. Pellegrino da Silva, H. Hakonarson, S.A. Sandaradura, Y. Guo, J. Christodoulou, J. Lagopoulos, P. Grattan-Smith, and V.S.C. Fung

CME Course Video

Reflections: Neurology and the Humanities**98 Patience**

J.N. LaBuzetta

Audio

NeuroImages**99 Diagnosis and treatment evaluation of in-stent restenosis of carotid artery stenting using optical coherence tomography**

R. Liu, Q. Yin, M. Li, R. Ye, W. Zhu, and X. Liu

Resident & Fellow Section**101 Pearls & Oysters: Challenging diagnosis of Gerstmann-Sträussler-Scheinker disease: Clinical and imaging findings**

M.J. Kang, J. Suh, S.S. An, S.Y. Kim, and Y.H. Park

e161 Clinical Reasoning: A 14-year-old girl with headache, seizures, and confusion

L. Xiao, W. Gu, B. Jiao, Y. Liu, and X. Yang

e168 Teaching NeuroImages: Leigh-like features expand the picture of PMPCA-related disorders

A. Rubegni, R. Pasquariello, C. Dosi, G. Astrea, R. Canapicchi, F.M. Santorelli, and C. Nesti

e170 Teaching Video NeuroImages: A 20-year-old man with distal paresthesia

A. Stafford and C. Osman

Video

Global Perspectives**104 Barriers to diagnosis and management of CNS infections in Indonesia**

D. Imran, S. Satiti, P. Sugianto, R. Estiasari, K. Maharani, D. Pangeran, P.W. Andini, B. Munir, A.H.P. Mawuntu, N.M. Susilawathi, K. Ritarwan, O.S. Hartanto, M. Frida, A.R. Ganiem, D. Gunawan, S. Dian, A.A.R. Sudewi, and R. van Crevel

Disputes & Debates: Editors' Choice**107 Editors' note: Teaching NeuroImages: DWI and EEG findings in Creutzfeldt-Jakob disease**

A. Lewis and S. Galetta

107 Reader response: Teaching NeuroImages: DWI and EEG findings in Creutzfeldt-Jakob disease

J. Yuan and W. Hu

108 Author response: Teaching NeuroImages: DWI and EEG findings in Creutzfeldt-Jakob disease

A. Ganesh and M.M.C. Yeung

109 Editors' note: Practice guideline recommendations summary: Disease-modifying therapies for adults with multiple sclerosis: Report of the Guideline Development, Dissemination, and Implementation Subcommittee of the American Academy of Neurology

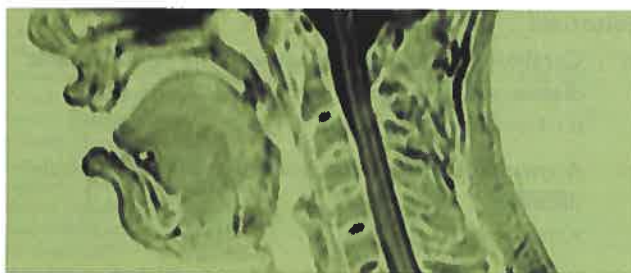
A. Lewis and S. Galetta

109 Reader response: Practice guideline recommendations summary: Disease-modifying therapies for adults with multiple sclerosis: Report of the Guideline Development, Dissemination, and Implementation Subcommittee of the American Academy of Neurology

L. Saltonstall

110 Author response: Practice guideline recommendations summary: Disease-modifying therapies for adults with multiple sclerosis: Report of the Guideline Development, Dissemination, and Implementation Subcommittee of the American Academy of Neurology

A. Rae-Grant

Correction**112 Practice guideline recommendations summary: Disease-modifying therapies for adults with multiple sclerosis: Report of the Guideline Development, Dissemination, and Implementation Subcommittee of the American Academy of Neurology****Department****In the Next Issue of *Neurology******Cover image**

MRI sagittal T2 of a 20-year-old man with progressive distal paresthesia. Colorized by Cindy Abair, *Neurology* Senior Graphics Editor. See page e170