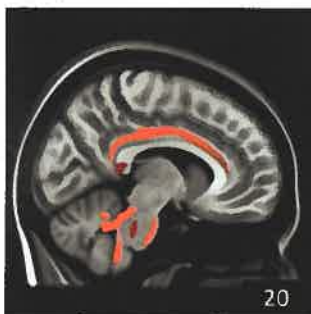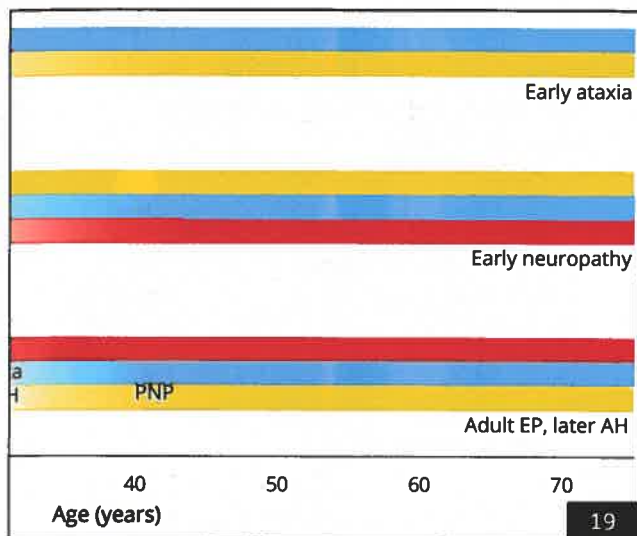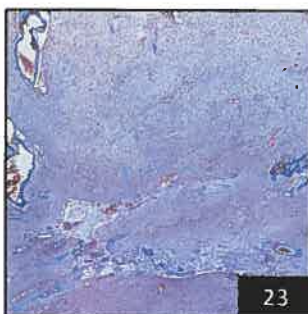


20



23

Select figures listed on the Table of Contents only appear within the full-length articles online.

In Focus

- 1 **Spotlight on the January 1 issue**
- 2 **This Week's Neurology® Podcast**

Acknowledgment to Reviewers

- 3 **Message from the Editors to our Reviewers**
R.A. Gross, B.B. Worrall, A.A. Amato, G.D. Cascino, O. Ciccarelli, J.R. Corboy, J.O. Dalmau, R.F. Gottesman, M. Grossman, J.J. Millichap, J.W. Mink, S.M. Pulst, and R.J. Uitti

Editorials

- 13 **Naming things: Its importance in youth with epilepsy**
B.P. Hermann and B. Tolchin

- 15 **Misdiagnosis of multiple sclerosis: If you have a hammer, everything looks like a nail?**
W.J. Brownlee

Articles: Short Format

Full articles at Neurology.org/N

- 17 **Noninvasive identification of seizure lateralization in children: Name that thing**
M.J. Hamberger, W.S. MacAllister, W.T. Seidel, R.M. Busch, C.M. Salinas, P. Klaas, and M.L. Smith
➔ Editorial, p. 13
- 18 **Continuous EEG is associated with favorable hospitalization outcomes for critically ill patients**
C.E. Hill, L.J. Blank, D. Thibault, K.A. Davis, N. Dahodwala, B. Litt, and A.W. Willis
🎧 Podcast
- 19 **Trajectories of motor abnormalities in milder phenotypes of ataxia telangiectasia**
N.J.H. van Os, A. Hensiek, J. van Gaalen, A.M.R. Taylor, M. van Deuren, C.M.R. Weemaes, M.A.A.P. Willemsen, and B.P.C. van de Warrenburg
- 20 **White matter differences between essential tremor and Parkinson disease**
M.R. Juttukonda, G. Franco, D.J. Englot, Y.-C. Lin, K.J. Petersen, P. Trujillo, P. Hedera, B.A. Landman, H. Kang, M.J. Donahue, P.E. Konrad, B.M. Dawant, and D.O. Claassen
- 21 **CSF β -amyloid₄₂ and risk of freezing of gait in early Parkinson disease**
R. Kim, J. Lee, H.-J. Kim, A. Kim, M. Jang, B. Jeon, and U.J. Kang
- 22 **High prevalence of neutralizing antibodies after long-term botulinum neurotoxin therapy**
P. Albrecht, A. Jansen, J.-I. Lee, M. Moll, M. Ringelstein, D. Rosenthal, H. Bigalke, O. Aktas, H.-P. Hartung, and H. Hefter
➔ CME Course
- 23 **Developmental venous anomaly in adult patients with diffuse glioma: A clinically relevant coexistence?**
A. Roux, M. Edjlali, S. Porelli, A. Tauziède-Espariat, M. Zanella, E. Dezamis, G. Zah-Bi, M. Sanson, S. Puget, L. Capelle, P. Varlet, C. Oppenheim, and J. Pallud
- 24 **Long-term intake of vegetables and fruits and subjective cognitive function in US men**
C. Yuan, E. Fondell, A. Bhushan, A. Ascherio, O.I. Okereke, F. Grodstein, and W.C. Willett
➔ CME Course

➔ Ahead of Print Articles and Editorials

NPub.org/aheadofprint
Continued

What's Happening

- 25 **What's happening in *Neurology****

Views & Reviews

- 26 **Misdiagnosis of multiple sclerosis: Impact of the 2017 McDonald criteria on clinical practice**

A.J. Solomon, R.T. Naismith, and A.H. Cross

📺 Editorial, p. 15

Medical Hypothesis

- 34 **A theory for polymicrogyria and brain arteriovenous malformations in HHT**

J.M. Klostranec, L. Chen, S. Mathur, J. McDonald, M.E. Faughnan, F. Ratjen, and T. Krings

Clinical/Scientific Notes

- 43 **Estimating the prevalence at death of CTE neuropathology among professional football players**

Z.O. Binney and K.E. Bachynski

Visions

- 46 **Facial paralysis in an Inupiaq ceremonial mask**

R.S. El-Mallakh and M. Hartman

Video NeuroImages

- 48 **Corneomandibular reflex in a patient with pontine hemorrhage without impaired consciousness**

M. Caballero-Ávila, E. Juanola, A. Izquierdo, A. Martínez-Domeño, and J. Martí-Fàbregas

📺 Video

Resident & Fellow Section

- 50 **Education Research: Electronic patient portal enrollment and no-show rates within a neurology resident clinic**

K. Shah, A. Alshammaa, M. Affan, L. Schultz, T. Walbert, and I. Zaman

- e76 **Clinical Reasoning: A 17-year-old baseball player with right hand weakness**

C. Vachon and A. Abu Libdeh

- e81 **Teaching NeuroImages: Melkersson-Rosenthal syndrome with permanent bilateral facial weakness**

F. Rossi, N. Tsakadze, E.M. Rossi, and M. Hoffmann

- e82 **Teaching Video NeuroImages: Oculogyric crises in a 10-year-old girl**

R. Suthar, N. Sankhyan, and P. Singhi

📺 Video

Disputes & Debates: Editors' Choice

- 55 **Editors' note: Right Brain: Withholding treatment from a child with an epileptic encephalomyopathy**

A. Ganesh and S. Galetta

- 55 **Reader response: Right Brain: Withholding treatment from a child with an epileptic encephalomyopathy**

N.K. Sethi

- 56 **Reader response: Right Brain: Withholding treatment from a child with an epileptic encephalomyopathy**

T.J. Janus

- 56 **Reader response: Right Brain: Withholding treatment from a child with an epileptic encephalomyopathy**

K.K. Tuck

- 57 **Author response: Right Brain: Withholding treatment from a child with an epileptic encephalomyopathy**

A. Rothstein and A. Lewis

Department

In the Next Issue of *Neurology**



📺 **Cover image**

Carved in the late 1800s by the Inupiak people of North America, this storytelling mask depicts an adult human with facial paralysis. Reprinted with permission from the Portland Art Museum, Oregon.

See page 46