

# Neurology<sup>®</sup>

## Table of Contents

Volume 86, Number 18, May 3, 2016

Neurology.org

THE MOST WIDELY READ AND HIGHLY CITED PEER-REVIEWED  
NEUROLOGY JOURNAL






### IN FOCUS




- 1651 Spotlight on the May 3 Issue  
1675 This Week's *Neurology*<sup>®</sup> Podcast

### EDITORIALS

- 1652 Combining rTMS and CIMT: A "one-size-fits-all" therapy for congenital hemiparesis?  
*M. Staudt and A.M. Gordon*
- 1655 Autoimmune encephalitis: A more treatable tragedy if diagnosed early  
*T.L. Vollmer and M. McCarthy*
- 1657 Voltage-gated potassium channel antibodies: Game over  
*F. Graus and M.P. Gorman*

### ARTICLES

- 1659 Brain stimulation and constraint for perinatal stroke hemiparesis: The PLASTIC CHAMPS Trial  
*A. Kirton, J. Andersen, M. Herrero, A. Nettel-Aguirre, L. Carsolio, O. Damji, J. Keess, A. Mineyko, J. Hodge, and M.D. Hill*  
  Editorial, p. 1652
- 1668 Systemic right-to-left shunts, ischemic brain lesions, and persistent migraine activity  
*H. Koppen, I.H. Palm-Meinders, W.H. Mess, R.W. Keunen, G.M. Terwindt, L.J. Launer, M.A. van Buchem, M.C. Kruit, and M.D. Ferrari*
- 1676 Ventral tegmental area deep brain stimulation for refractory chronic cluster headache  
*H. Akram, S. Miller, S. Lagrata, J. Hyam, M. Jahanshahi, M. Hariz, M. Matharu, and L. Zrinzo*  
 
- 1683 Rituximab treatment for autoimmune limbic encephalitis in an institutional cohort  
*W.-J. Lee, S.-T. Lee, J.-I. Byun, J.-S. Sunwoo, T.-J. Kim, J.-A. Lim, J. Moon, H.S. Lee, Y.-W. Shin, K.-J. Lee, S. Kim, K.-H. Jung, K.-Y. Jung, K. Chu, and S.K. Lee*  
 Editorial, p. 1655

- 1692 The relevance of VGKC positivity in the absence of LGI1 and Caspr2 antibodies  
*A. van Sonderen, M.W.J. Schreurs, M.A.A.M. de Bruijn, S. Boukhrissi, M.M.P. Nagtzaam, E.S.P. Hulsenboom, R.H. Enting, R.D. Thijs, P.W. Wirtz, P.A.E. Sillevs Smitt, and M.J. Titulaer*  
Editorial, p. 1657
- 1700 Quantitative MRI reveals decelerated fatty infiltration in muscles of active FSHD patients  
*B. Janssen, N. Voet, A. Geurts, B. van Engelen, and A. Heerschap*  

- 1708 Association between oral fluoroquinolones and seizures: A self-controlled case series study  
*C.S.L. Chui, E.W. Chan, A.Y.S. Wong, A. Root, I.J. Douglas, and I.C.K. Wong*
- 1716 Lamotrigine use in pregnancy and risk of orofacial cleft and other congenital anomalies  
*H. Dolk, H. Wang, M. Loane, J. Morris, E. Garne, M.-C. Addor, L. Arriola, M. Bakker, I. Barisic, B. Doray, M. Gatt, K. Kallen, B. Khoshnood, K. Klungsoyr, A.-M. Lahesmaa-Korpinen, A. Latos-Bielenska, J.P. Mejnartowicz, V. Nelen, A. Neville, M. O'Mahony, A. Pierini, A. Rißmann, D. Tucker, D. Wellesley, A. Wiesel, and L.T.W. de Jong-van den Berg*  

- 1726 Supernumerary phantom limbs in ICU patients with acute inflammatory demyelinating polyneuropathy  
*A.N. Melinyshyn, T.E. Gofton, and V. Schulz*
- 1729 A randomized, controlled, double-blind, crossover trial of zonisamide in myoclonus-dystonia  
*E. Hainque, M. Vidailhet, N. Cozic, F. Charbonnier-Beaupel, S. Thobois, C. Tranchant, V. Brochard, G. Glibert, S. Drapier, E. Mutez, A. Doe De Maindreville, T. Lebouvier, C. Hubsch, B. Degos, C. Bonnet, D. Grabli, A.-P. Legrand, A. Méneret, J.-P. Azulay, A. Bissery, N. Zahr, F. Clot, A. Mallet, S. Dupont, E. Apartis, J.-C. Corvol, and E. Roze*  


CONTINUED

# Neurology®

## Table of Contents

continued



- 1736 Prevalence, characteristics, and survival of frontotemporal lobar degeneration syndromes  
*I.T.S. Coyle-Gilchrist, K.M. Dick, K. Patterson, P. Vázquez Rodríguez, E. Wehmann, A. Wilcox, C.J. Lansdall, K.E. Dawson, J. Wiggins, S. Mead, C. Brayne, and J.B. Rowe*

**OPEN**

### NEUROIMAGES

- 1744 Arterial spin labeling shows pre-epileptic tuber hyperperfusion in tuberous sclerosis complex  
*M. Hully, D. Grevent, D. Breuillard, F. Brunelle, N. Chemaly, R. Calmon, N. Boddart, and R. Nabbout*

### VIDEO NEUROIMAGES

- 1746 Pupillary sign of aberrant regeneration of the third nerve  
*O.R. Rosenvald and S. Lessell*



### RESIDENT & FELLOW SECTION

- e190 Clinical Reasoning: A 38-year-old man with respiratory failure and progressive leg weakness  
*P. McIntosh and C. Karam*

- e195 Pearls & Oysters: Looking up the anatomy of looking up  
*M.B. Abid, D. Soon, R. Rathakrishnan, P. Zhao, C. Tan, and L.L.L. Yeo*



- e199 Teaching NeuroImages: Spontaneous resolution of a giant intracranial arachnoid cyst  
*Z. Liu, J. Li, and J. Xu*

- e201 Teaching NeuroImages: Macrocerebellum and optic atrophy in a young boy  
*W.B.V. de Rezende Pinto, P.V.S. de Souza, G.N. de Rezende Batistella, and A.S. Bulle Oliveira*

### WRITECLICK® EDITOR'S CHOICE

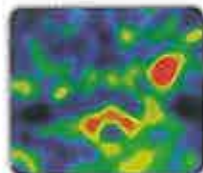
- 1747 Increased CSF biomarkers of angiogenesis in Parkinson disease  
*S. Lattanzi, M. Silvestrini, M.M. Verbeek, B. Mollenhauer; Author Response: D. Lindqvist, S. Janelidze, O. Hansson*

### DEPARTMENT

In the Next Issue of *Neurology*®

Podcast at [Neurology.org](http://Neurology.org) CME Video Patient Page LOE classification LOE recommendation

[the way on Facebook](https://www.facebook.com/Neurologyfan) [tinyurl.com/neurologyfan](https://www.tinyurl.com/neurologyfan) [twitter](https://twitter.com/Neurologyfan) [twitter.com/GreenJournal](https://twitter.com/GreenJournal)



**Cover image:** Brain MRI of a 2-month-old patient with tuberous sclerosis. Left temporal pole tuber is seen on axial T2-weighted image with corresponding increased temporal blood flow. See page 1744.

Look for **Publish Ahead of Print** articles and editorials under the Ahead of Print tab at [Neurology.org](http://Neurology.org)