

# Neurology<sup>®</sup>

## Table of Contents

Volume 86, Number 10, March 8, 2016  
Neurology.org

THE MOST WIDELY READ AND HIGHLY CITED PEER-REVIEWED  
NEUROLOGY JOURNAL



### IN FOCUS

- 883 Spotlight on the March 8 Issue  
946 This Week's Neurology<sup>®</sup> Podcast

### EDITORIALS

- 884 Spinal muscular atrophy: A preliminary result toward new therapy  
*Y. Nevo and C. Wang*
- 886 Stroke systems of care: The sum is greater than the parts  
*J.J. Fletcher and J.J. Majersik*
- 888 Pursuing "model care" of transient ischemic attacks  
*J.F. Burke and M. McDermott*

### ARTICLES

- 890 Results from a phase 1 study of nusinersen (ISIS-SMN<sub>Rx</sub>) in children with spinal muscular atrophy  
*C.A. Chiriboga, K.J. Swoboda, B.T. Darras, S.T. Iannaccone, J. Montes, D.C. De Vivo, D.A. Norris, C.F. Bennett, and K.M. Bishop*  
**OPEN** Editorial, p. 884
- 898 Integrated systems of stroke care and reduction in 30-day mortality: A retrospective analysis  
*A. Ganesh, P. Lindsay, J. Fang, M.K. Kapral, R. Côté, I. Joiner, A.M. Hakim, and M.D. Hill*  
Editorial, p. 886
- 905 Incontinence and gait disturbance after intraventricular extension of intracerebral hemorrhage  
*D. Woo, A.J. Kruger, P. Sekar, M. Haverbusch, J. Osborne, C.J. Moomaw, S. Martini, S.M. Hosseini, S. Ferioli, B.B. Worrall, M.S.V. Elkind, G. Sung, M.L. James, F.D. Testai, C.D. Langefeld, J.P. Broderick, S. Koch, and M.L. Flaherty*
- 912 Pseudotumoral presentation of cerebral amyloid angiopathy-related inflammation  
*S. Ronsin, G. Deiana, A.F. Geraldo, F. Durand-Dubief, L. Thomas-Maisonneuve, M. Formaglio, V. Desestret, D. Meyronet, N. Nighoghossian, Y. Berthezène, J. Honnorat, and F. Ducray*

- 920 Long-term safety and efficacy of teriflunomide: Nine-year follow-up of the randomized TEMSO study  
*P. O'Connor, G. Comi, M.S. Freedman, A.E. Miller, L. Kappos, J.-P. Bouchard, C. Lebrun-Frenay, J. Mares, M. Benamor, K. Thangavelu, J. Liang, P. Truffinet, V.J. Lawson, and J.S. Wolinsky, for the Teriflunomide Multiple Sclerosis Oral (TEMSO) Trial Group and the MRI-AC in Houston, Texas*  
**OPEN**
- 931 Holmes tremor: Clinical description, lesion localization, and treatment in a series of 29 cases  
*G.B. Raina, M.G. Cersosimo, S.S. Folgar, J.C. Giugni, C. Calandra, J.P. Paviolo, V.A. Tkachuk, C. Zuñiga Ramirez, A.L. Tschopp, D.S. Calvo, L.A. Pellene, M.C. Uribe Roca, M. Velez, R.J. Giannoula, M.M. Fernandez Pardal, and F.E. Micheli*
- 939 Antiepileptic use for epilepsy and nonepilepsy disorders: A population-based study (1998-2013)  
*C. Leong, M.M. Mamdani, T. Gomes, D.N. Juurlink, E.M. Macdonald, and M. Yogendran*

### VIEWS & REVIEWS

- 947 Transient ischemic attack service provision: A review of available service models  
*A. Ranta and P.A. Barber*  
 Editorial, p. 888
- 954 STXBP1 encephalopathy: A neurodevelopmental disorder including epilepsy  
*H. Stamberger, M. Nikanorova, M.H. Willemssen, P. Accorsi, M. Angriman, H. Baier, I. Benkel-Herrenbrueck, V. Benoit, M. Budetta, A. Caliebe, G. Cantalupo, G. Capovilla, G. Casara, C. Courage, M. Deprez, A. Destrée, R. Dilena, C.E. Erasmus, M. Fannemel, R. Fjær, L. Giordano, K.L. Helbig, H.O. Heyne, J. Klepper, G.J. Kluger, D. Lederer, M. Lodi, O. Maier, A. Merckenschlager, N. Michelberger, C. Minetti, H. Muhle, J. Phalin, K. Ramsey, A. Romeo, J. Schallner, I. Schanze, M. Shinawi, K. Slegers, K. Sterbova, S. Syrbe, M. Traverso, A. Tzschach, P. Uldall, R. Van Coster, H. Verhelst, M. Viri, S. Winter, M. Wolff, M. Zenker, L. Zoccante, P. De Jonghe, I. Helbig, P. Striano, J.R. Lemke, R.S. Møller, and S. Weckhuysen*

CONTINUED

# Neurology<sup>®</sup>

## Table of Contents

*continued*



- 963 Antibiotic-associated encephalopathy  
*S. Bhattacharyya, R.R. Darby, P. Raibagkar,  
L.N. Gonzalez Castro, and A.L. Berkowitz*


### CLINICAL/SCIENTIFIC NOTES

- 972 Acute retinal necrosis in multiple sclerosis:  
A neuroimmunologic challenge!  
*Z. Sheikh, S. Jain, and M. Hillen*
- 974 A new type of cervical vertigo: Head motion-induced  
spells in acute neck pain  
*T. Brandt and D. Huppert*


### REFLECTIONS: NEUROLOGY AND THE HUMANITIES

- 976 Seahorses  
*A.I. Rae*


### VIDEO NEUROIMAGES

- 977 Value of self-induced plantar reflex in distinguishing  
Babinski from withdrawal  
*S.A. Sohrab and D. Gelb*  


### RESIDENT & FELLOW SECTION

- e97 Clinical Reasoning: Seizures from the neglected lobe  
*W. Muhlhofer, B. Paul, G. Lin, and N. Singhal*  


- e101 Clinical Reasoning: A 58-year-old woman with loss of  
vision in her left eye  
*G.P.H. Ho, K.T. Brizzi, D.M. Meredith, E.R. Laws, Jr., and  
A.L. Berkowitz*

- e108 Teaching Video NeuroImages: Vertical supranuclear  
ophthalmoparesis: A diagnostic pearl for  
Niemann-Pick C  
*A. Gupta, N. Kumar, R. Saharan, P. Rastogi, V.Y. Vishnu,  
and V. Lal*  


### WRITECLICK® EDITOR'S CHOICE

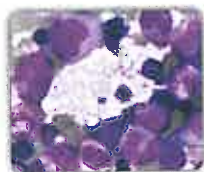
- 978 ADCY5 mutations are another cause of benign  
hereditary chorea  
*J.C. Morgan, J.A. Kurek, J. Davis, K.D. Sethi;  
Author Response: N.E. Mencacci, R. Erro,  
K.P. Bhatia*
- 979 Standard chemoradiation for glioblastoma results in  
progressive brain volume loss  
*M.C. Chamberlain; Author Response: J. Dietrich,  
M. Prust*

### DEPARTMENT

In the Next Issue of *Neurology*®

 Podcast at [Neurology.org](http://Neurology.org)  CME  Video  Patient Page  LOE classification  LOE recommendation

 [Facebook](https://www.facebook.com/Neurologyfan) [tinyurl.com/neurologyfan](http://tinyurl.com/neurologyfan)  [twitter.com/GreenJournal](https://twitter.com/GreenJournal)



**Cover image:** Photomicrograph from bone marrow aspirate shows presence of large cells with abundant amount of cytoplasm filled with multiple vacuoles suggesting the morphology of Niemann-Pick disease. See page e108.

---

Look for **Publish Ahead of Print** articles and editorials under the Ahead of Print tab at [Neurology.org](http://Neurology.org)

---