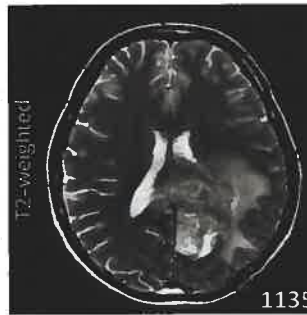
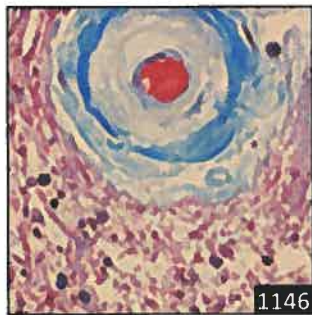
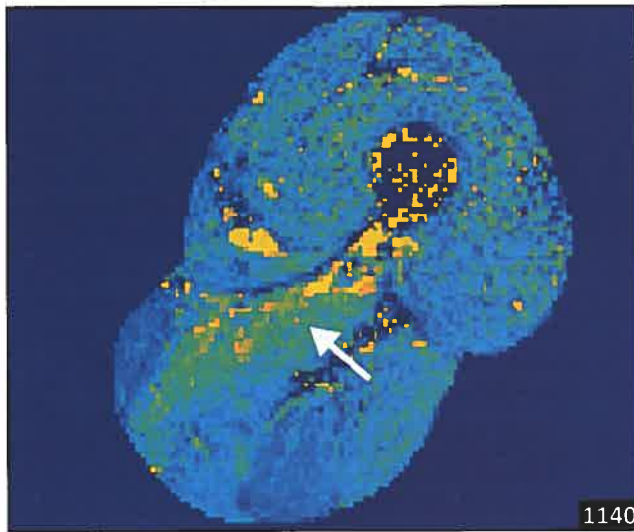Select figures listed on the Table of Contents only appear within the full-length articles online.

In Focus

- 1123 **Spotlight on the June 11 issue**
- 1124 **This Week's *Neurology*® Podcast**

Editorials

- 1125 **An association between bipolar disorder and Parkinson disease: When mood makes you move**
G.M. Pontone and G. Koch
- 1127 **Recanalization for large vessel stroke: Necessary but not sufficient for reperfusion**
M.B. Maas and G. Kapinos
- 1129 **Thrombolysis in young adults with acute ischemic stroke: Quicker may be better**
V. Papavasileiou and L.B. Goldstein

- 1131 **Neurology and the homeless: How can we do better?**
M. Swash and J.C. Probasco

Articles: Short Format

Full articles at Neurology.org/N

- 1133 **Bipolar disorder and risk of Parkinson disease: A nationwide longitudinal study**
M.-H. Huang, C.-M. Cheng, K.-L. Huang, J.-W. Hsu, Y.-M. Bai, T.-P. Su, C.-T. Li, S.-J. Tsai, W.-C. Lin, T.-J. Chen, and M.-H. Chen
📌 Editorial, p. 1125
- 1134 **Capturing acute vertigo: A vestibular event monitor**
A.S. Young, C. Lechner, A.P. Bradshaw, H.G. MacDougall, D.A. Black, G.M. Halmagyi, and M.S. Welgampola
- 1135 **Imaging necrosis during treatment is associated with worse survival in EORTC 26101 study**
M. Nowosielski, T. Gorlia, J.E.C. Bromberg, F. Sahm, I. Harting, P. Kickingereder, A.A. Brandes, M.J.B. Taphoorn, W. Taal, J. Domont, A. Idnbaih, M. Campone, P.M. Clement, M. Weller, M. Fabbro, E. Le Rhun, M. Platten, V. Golfopoulos, M.J. van den Bent, M. Bendszus, and W. Wick
- 1136 **Long-term disability progression of pediatric-onset multiple sclerosis**
K.A. McKay, J. Hillert, and A. Manouchehrinia
Open Access Article
- 1137 **Early hemodynamic predictors of good outcome and reperfusion injury after endovascular treatment**
C. Baracchini, F. Farina, A. Palmieri, C. Kulyk, A. Pieroni, F. Viaro, G. Cester, F. Causin, and R. Manara
📌 Editorial, p. 1127
- 1138 **Thrombolysis in young adults with stroke: Findings from Get With The Guidelines–Stroke**
J.A. Dodds, Y. Xian, S. Sheng, G.C. Fonarow, D.L. Bhatt, R. Matsouaka, L.H. Schwamm, E.D. Peterson, and E.E. Smith
📌 CME Course 📌 Editorial, p. 1129
- 1139 **Width and neurophysiologic properties of tissue bridges predict recovery after cervical injury**
K. Vallotton, E. Huber, R. Sutter, A. Curt, M. Hupp, and P. Freund
Open Access Article
- 1140 **Lower extremity muscle pathology in myotonic dystrophy type 1 assessed by quantitative MRI**
L. Heskamp, M. van Nimwegen, M.J. Ploegmakers, G. Bassez, J.-F. Deux, S.A. Cumming, D.G. Monckton, B.G.M. van Engelen, and A. Heerschap
Open Access Article

📌 Ahead of Print Articles and Editorials

NPub.org/aheadofprint

Continued

1141 **Prevalence of highly effective contraception use by women with epilepsy**

A.G. Herzog, H.B. Mandle, and D.B. MacEachern

1142 **Hospital admission and readmission among homeless patients with neurologic disease**

N. Rosendale, E.L. Guterman, J.P. Betjemann, S.A. Josephson, and V.C. Douglas

📍 CME Course 📍 Editorial, p. 1131

What's Happening

1143 **What's happening in *Neurology*[®] *Clinical Practice***

1144 **What's happening in *Neurology*[®] *Neuroimmunology & Neuroinflammation***

1145 **What's happening in Without Borders**

Views & Reviews

1146 **CNS small vessel disease: A clinical review**

R.J. Cannistraro, M. Badi, B.H. Eidelman, D.W. Dickson, E.H. Middlebrooks, and J.F. Meschia

Reflections: Neurology and the Humanities

1157 **How I learned to stop researching and live in the moment**

B. Sadler and J.E. Sadler

🔊 Audio

Resident & Fellow Section

1159 **Opinion and Special Articles: Mentoring in neurology: Where are the clinician-scientists? Is residency to blame?**

A. Ellaithy and N.S. Narayanan

e2832 **Clinical Reasoning: A 47-year-old man with diffuse white matter disease and rapidly progressive dementia**

D.G. Di Luca, J. Landman, M.R. Ortega, S.H. Gultekin, and X. Sun

e2838 **Teaching NeuroImages: Persistent anterograde amnesia due to sequential, bilateral vascular damage to the Papez circuit**

F.H.G. Porto, P.L. de Almeida, and K.R. Daffner

e2840 **Teaching NeuroImages: The tetraplegic gardener: A case of CNS nocardiosis in an immunocompetent patient**

V.B. Gadelha, F.A. Nascimento, V.K. Fiamoncini, J.A.S. Freitas, M.C. Lange, B.C.A. Teixeira, E.M. Novak, and H.A.G. Teive

Disputes & Debates: Editors' Choice

1163 **Editors' note: Practice guideline update recommendations summary: Disorders of consciousness: Report of the Guideline Development, Dissemination, and Implementation Subcommittee of the American Academy of Neurology; the American Congress of Rehabilitation Medicine; and the National Institute on Disability, Independent Living, and Rehabilitation Research**

J.E. Siegler III and S. Galetta

1163 **Reader response: Practice guideline update recommendations summary: Disorders of consciousness: Report of the Guideline Development, Dissemination, and Implementation Subcommittee of the American Academy of Neurology; the American Congress of Rehabilitation Medicine; and the National Institute on Disability, Independent Living, and Rehabilitation Research**

T.G. Phan, U. Seneviratne, and H. Ma

1164 **Author response: Practice guideline update recommendations summary: Disorders of consciousness: Report of the Guideline Development, Dissemination, and Implementation Subcommittee of the American Academy of Neurology; the American Congress of Rehabilitation Medicine; and the National Institute on Disability, Independent Living, and Rehabilitation Research**

M.J. Armstrong, J.T. Giacino, D.I. Katz, N.D. Schiff, J. Whyte, E.J. Ashman, S. Ashwal, R. Barbano, F.M. Hammond, S. Laureys, G.S.F. Ling, R. Nakase-Richardson, R.T. Seel, S. Yablon, T.S.D. Getchius, and G.S. Gronseth

1165 **Editors' note: Clinical Reasoning: A 54-year-old woman with confusion and visual disturbances**

J.E. Siegler III and S. Galetta

1165 **Reader response: Clinical Reasoning: A 54-year-old woman with confusion and visual disturbances**

L. Pollak

1166 **Author response: Clinical Reasoning: A 54-year-old woman with confusion and visual disturbances**

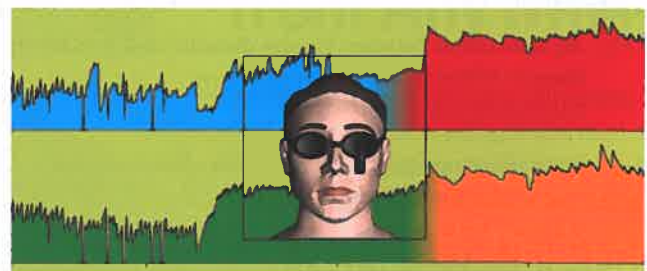
K.C. Rossi, R. Brandstadter, M.C. Fields, and S. Shin

Correction

1166 **Quality of life predicts outcome of deep brain stimulation in early Parkinson disease**

Department

In the Next Issue of *Neurology*[®]



📍 **Cover image**

Spontaneous nystagmus recorded in the upright position in a patient with Ménière disease affecting the left ear. Stylized by Kaitlyn Aman Ramm, *Neurology* Editorial Assistant

See page 1134