

Neurology[®]

Table of Contents

Volume 87, Number 18, November 1, 2016
Neurology.org

THE MOST WIDELY READ AND HIGHLY CITED PEER-REVIEWED
NEUROLOGY JOURNAL



IN FOCUS

1851 Spotlight on the November 1 Issue

1953 This Week's *Neurology*[®] Podcast

EDITORIALS

1852 How long should we wait to start oral anticoagulation after cardioembolic stroke?

B. Cucchiara

1854 Rebleeding in cerebral amyloid angiopathy: Inside out or outside in?

F. Fazekas and M.J.H. Wermer

ARTICLES

1856 Early start of DOAC after ischemic stroke: Risk of intracranial hemorrhage and recurrent events
D.J. Seiffge, C. Traenka, A. Polymeris, L. Hert, N. Peters, P. Lyrer, S.T. Engelter, L.H. Bonati, and G.M. De Marchis
Editorial, p. 1852

1863 Cortical superficial siderosis predicts early recurrent lobar hemorrhage

D. Roongpiboonsopit, A. Charidimou, C.M. William, A. Lauer, G.J. Falcone, S. Martinez-Ramirez, A. Biffi, A. Ayres, A. Vashkevich, O.O. Awosika, J. Rosand, M.E. Guroi, S.B. Silverman, S.M. Greenberg, and A. Viswanathan

Editorial, p. 1854

1871 Quality of life at 6 months in the Idiopathic Intracranial Hypertension Treatment Trial

B.B. Bruce, K.B. Digre, M.P. McDermott, E.B. Schron, and M. Wall, on behalf of the NORDIC Idiopathic Intracranial Hypertension Study Group

1878 Trial of early noninvasive ventilation for ALS: A pilot placebo-controlled study

T.L. Jacobs, D.L. Brown, J. Baek, E.M. Migda, T. Funckes, and K.L. Gruis



1884 Posterior interosseous neuropathy: Supinator syndrome vs fascicular radial neuropathy

P. Bäumer, H. Kele, A. Xia, M. Weiler, D. Schwarz, M. Bendszus, and M. Pham

OPEN

1892 Prevalence of polyneuropathy in the general middle-aged and elderly population

R. Hanewinkel, J. Drenthen, M. van Oijen, A. Hofman, P.A. van Doorn, and M.A. Ikram

1899 Cluster headache and depression

M.A. Louter, L.A. Wilbrink, J. Haan, E.W. van Zwet, W.P.J. van Oosterhout, F.G. Zitman, M.D. Ferrari, and G.M. Terwindt



1907 Multifocal repetitive TMS for motor and mood

symptoms of Parkinson disease: A randomized trial
M. Brys, M.D. Fox, S. Agarwal, M. Biagioni, G. Dacpano, P. Kumar, E. Pirraglia, R. Chen, A. Wu, H. Fernandez, A.W. Shukla, J.-S. Lou, Z. Gray, D.K. Simon, A. Di Rocco, and A. Pascual-Leone



1916 Female advantage in verbal memory: Evidence of sex-specific cognitive reserve

E.E. Sundermann, P.M. Maki, L.H. Rubin, R.B. Lipton, S. Landau, and A. Biegon, for the Alzheimer's Disease Neuroimaging Initiative

1925 Distinct brain networks underlie cognitive dysfunction in Parkinson and Alzheimer diseases

P.J. Mattis, M. Niethammer, W. Sako, C.C. Tang, A. Nazem, M.L. Gordon, V. Brandt, V. Dhawan, and D. Eidelberg

1934 MRI-negative temporal lobe epilepsy: A network disorder of neocortical connectivity

D.N. Vaughan, G. Rayner, C. Tailby, and G.D. Jackson



1943 Cognition in school-age children exposed to levetiracetam, topiramate, or sodium valproate

R.L. Bromley, R. Calderbank, C.P. Cheyne, C. Rooney, P. Trayner, J. Clayton-Smith, M. García-Fiñana, B. Irwin, J.I. Morrow, R. Shallicross, and G.A. Baker, on behalf of the UK Epilepsy and Pregnancy Register



CONTINUED

Neurology®

Table of Contents

continued



CLINICAL/SCIENTIFIC NOTES

- 1954 HLA-DRB1 alleles in Immune-mediated necrotizing myopathy
Y. Ohnuki, S. Suzuki, T. Shiina, A. Uruha, Y. Watanabe, S. Suzuki, S. Izumi, J. Nakahara, K. Hamanaka, K. Takayama, N. Suzuki, and I. Nishino

NEUROIMAGES

- 1956 Wernicke encephalopathy: SWI detects petechial hemorrhages in mammillary bodies in vivo
E. Hattingen, A. Beyle, A. Müller, T. Klockgether, and C. Kornblum
- 1958 Strabismus from supernumerary extraocular muscle restriction
J.H. Peragallo and P.A. Hudgins

RESIDENT & FELLOW SECTION

- e215 Clinical Reasoning: Bacterial meningitis causing a neuromyelitis optica flare
F. Saab, M. Stutz, and L. Restrepo
- e219 Emerging Subspecialties in Neurology: Pediatric stroke and cerebrovascular disorders
M.E. Bernson-Leung and G.A. deVeber

- e223 Teaching NeuroImages: Noninfectious cyst as an unusual complication of deep brain stimulation
H.V. Gupta, M.K. Lyons, and S.H. Mehta

- e225 Teaching NeuroImages: Swirl sign and spot sign in intraparenchymal hematoma
B.A.J.M. Wagemans, S. Klinkenberg, and A.A. Postma

WRITECLICK® EDITOR'S CHOICE

- 1960 The APOSTEL recommendations for reporting quantitative optical coherence tomography studies
J.R. Cameron; Author Response: P. Albrecht, A. Cruz-Herranz, A. Petzold, W.A. Lagreze, A.U. Brandt
- 1960 Emerging Subspecialties in Neurology: Neuro-ophthalmology
S.V. Smith, A.G. Lee; Author Response: A. Desai, J. Stelzer, S. Desai

CORRECTION

- 1961 Comparative efficacy of fingolimod vs natalizumab: A French multicenter observational study
(WriteClick: Editor's Choice)

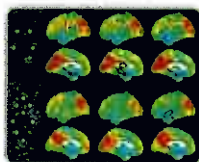
DEPARTMENT

In the Next Issue of *Neurology*®

Podcast at Neurology.org CME Video Patient Page LOE classification LOE recommendation



[tlnyurl.com/neurologyfan](https://www.facebook.com/neurologyfan) twitter.com/GreenJournal



Cover image: Voxel-wise functional MRI connectivity, calculated by clustering coefficient and eigenvector centrality, in controls, temporal lobe epilepsy (TLE) with hippocampal sclerosis, and MRI-negative TLE. Colorized by Cindy Abair, *Neurology* Senior Graphics Editor. See page 1934.

Look for **Publish Ahead of Print** articles and editorials under the Ahead of Print tab at Neurology.org