



MAYO CLINIC PROCEEDINGS

www.mayoclinicproceedings.org



Table of Contents

May 2019 Volume 94 Number 5

The June online issue of *Proceedings* will be available by Monday, June 3.
Sign up for an alert to the online Table of Contents at www.mayoclinicproceedings.org

In The Limelight

739 In the Limelight: May 2019

Karl A. Nath

Editorials

742 Herpes Zoster, a Rash of Cerebrovascular Events

Maria A. Nagel and Andrew N. Bubak

745 New Guidelines, Increasing Hypertension Numbers, Resistance and Resistance to Change?

Hector O. Ventura, Merrill H. Stewart, and Carl J. Lavie

748 Beyond Biomarkers: Machine Learning in Diagnosing Acute Kidney Injury

Bruce A. Molitoris

751 An Unexpected *FLNC* Phenotype: Expanding the Clinical Spectrum or a Second-Hit Disease Mechanism?

Jodie Ingles and Christopher Semsarian

754 The Compass: A New *Mayo Clinic Proceedings* Feature Dedicated to Topics in Bioethics and Health Humanities

Daniel K. Hall-Flavin and Richard R. Sharp

Commentary

757 Low Vitamin B12 and Parkinson Disease: Potential Link to Reduced Cholinergic Transmission and Severity of Disease

Stuart J. McCarter, Levi M. Teigen, Allison R. McCarter, Eduardo E. Benarroch, Erik K. St. Louis, and Rodolfo Savica

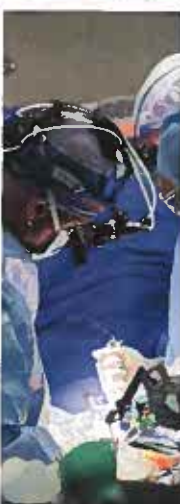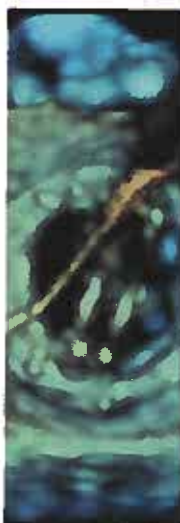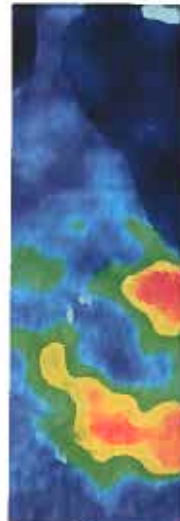
Original Articles

763 Analysis of Vascular Event Risk After Herpes Zoster From 2007 to 2014 US Insurance Claims Data

Brandon J. Patterson, Debora A. Rausch, Debra E. Irwin, Michael Liang, Songkai Yan, and Barbara P. Yawn

Herpes zoster was associated with an increased risk of composite events, transient ischemic attack, and stroke in adults in the period around diagnosis.

Continued





- 
- 776** **Prevalence of Apparent Treatment-Resistant Hypertension in the United States According to the 2017 High Blood Pressure Guideline**
Kershaw V. Patel, Xilong Li, Nitin Kondamudi, Muthiah Vaduganathan, Beverley Adams-Huet, Gregg C. Fonarow, Wanpen Vongpatanasin, and Ambarish Pandey 
- Patients often require multiple medications for blood pressure management but are frequently prescribed only 1 or 2 antihypertensive drug classes while still above their target blood pressure.
- 783** **Automated Continuous Acute Kidney Injury Prediction and Surveillance: A Random Forest Model**
Caitlyn Chiofalo, Nicolas Chbat, Erina Ghosh, Larry Eshelman, and Kianoush Kashani  
- The detection of acute kidney injury is often delayed. Using this prediction model, clinicians may gain more than 6 golden hours to prevent acute kidney injury.
- 793** **Optimization Sprints: Improving Clinician Satisfaction and Teamwork by Rapidly Reducing Electronic Health Record Burden**
Amber Sieja, Katie Markley, Jonathan Pell, Christine Gonzalez, Brian Redig, Patrick Kneeland, and Chen-Tan Lin  
- Teamwork and satisfaction improved after a short-term, intensive, multidisciplinary intervention designed to improve the experience using the electronic health record.
- 803** **Inflammation Is Strongly Associated With Cardiorespiratory Fitness, Sex, BMI, and the Metabolic Syndrome in a Self-reported Healthy Population: HUNT3 Fitness Study**
Erik Madssen, Eli-Anne Skaug, Ulrik Wisløff, Øyvind Ellingsen, and Vibeke Videm
- Low cardiorespiratory fitness should be considered a factor contributing to systemic inflammation. Reducing body weight and improving cardiorespiratory fitness may positively affect C-reactive protein levels.
- 811** **Hypertensive Diseases of Pregnancy Increase Risk of Readmission With Heart Failure: A National Readmissions Database Study**
Junaid Nizamuddin, Atul Gupta, Vijal Patel, Mohammed Minhaj, Sarah L. Nizamuddin, Ariel L. Mueller, Heba Naseem, Avery Tung, Sarosh Rana, and Sajid Shahul 
- In women with hypertensive disease of pregnancy, most readmissions with a diagnosis of heart failure after delivery occurred within 2 weeks of initial discharge.
- 820** **Treatment of Temporomandibular Dysfunction With Hypertonic Dextrose Injection (Prolotherapy): A Randomized Controlled Trial With Long-term Partial Crossover**
Wyndand Francois Louw, K. Dean Reeves, Stanley K.H. Lam, An-Lin Cheng, and David Rabago 
- In study participants with temporomandibular dysfunction, intra-articular dextrose prolotherapy was superior to lidocaine injections.

Brief Report

- 833** **Cardiorespiratory Fitness and the Risk of Serious Ventricular Arrhythmias: A Prospective Cohort Study**
Jari A. Laukkanen, Carl J. Lavie, Hassan Khan, Sudhir Kurl, and Setor K. Kunutsor

Clinical Practice Guidelines

- 842** **The International Society for the Study of Women's Sexual Health Process of Care for the Identification of Sexual Concerns and Problems in Women**
Sharon J. Parish, Steven R. Hahn, Sue W. Goldstein, Annamaria Giraldi, Sheryl A. Kingsberg, Lisa Larkin, Mary Jane Minkin, Vivien Brown, Kristin Christiansen, Rose Hartzell-Cushmanick, Alyse Kelly-Jones, Jordan Rullo, Richard Sadovsky, and Stephanie S. Faubion  

Special Article

- 857** **Communication Challenges: A Spotlight on New-Onset Refractory Status Epilepticus**
Teneille E. Gofton, Nora Wong, Lawrence J. Hirsch, and Sara E. Hocker 

Review



- 864** **Left Atrial Appendage Occlusion for The Unmet Clinical Needs of Stroke Prevention in Nonvalvular Atrial Fibrillation**
David R. Holmes Jr., Mohamad Alkhouli, and Vivek Reddy

Concise Review for Clinicians—CME Credit Offered

- 875** **Acute Flaccid Myelitis: A Clinical Overview for 2019**
Yasaman Fatemi and Rana Chakraborty 

Please note that articles with an "e" page designation are available only in the online version of the Journal at www.mayoclinicproceedings.org


Residents' Clinic

- 882** **63-Year-Old Man With Fever, Chills, and Myalgias**
Alexander J. Ryu and Jeffrey B. Geske 
- 887** **71-Year-Old Man Presenting With Postoperative Chest Tightness**
Robert C. Ward, Megha Prasad, and Robert L. Frye
- e61** **69-Year-Old Woman With Fevers, Diarrhea, and Abdominal Pain**
Courtney E. Harris, Claire L. Jansson-Knodell, and Abinash Virk 


Thematic Review Series on Neurosciences—CME Credit Offered

- 892** **Mesenchymal Stromal Cell Therapies for Neurodegenerative Diseases**
Nathan P. Staff, David T. Jones, and Wolfgang Singer

Case Report

- 906** **A Novel Truncating Variant in *FLNC*-Encoded Filamin C May Serve as a Proarrhythmic Genetic Substrate for Arrhythmogenic Bileaflet Mitral Valve Prolapse Syndrome**
Sahej Bains, David J. Tester, Samuel J. Asirvatham, Peter A. Noseworthy, Michael J. Ackerman, and John R. Giudicessi 

Continued



Letters to the Editor

- 914** **Factitial Panniculitis Associated With Cosmetic Filler**
Zerelda Esquer Gamigos, Audrey N. Schuetz, and Margot S. Peters
- 915** **Probable Invasive Pulmonary Cryptococcosis and Possible Cryptococcal Empyema in CLL Treated With Frontline Ibrutinib**
Amber B. Koehler, Prakhar Vijayvargiya, and Wei Ding
- 917** **Chronic and Complex Myofascial Pain Syndromes in Chronic Abdominal Wall Pain**
George Comerci Jr., Brian M. Shelley, and Benson R. Daitz
- 917** **In Reply: Chronic and Complex Myofascial Pain Syndromes in Chronic Abdominal Wall Pain**
Amrit K. Kamboj, Patrick Hoversten, and Amy S. Oxentenko
- 918** **Acute Myocardial Infarction During Pregnancy and the Puerperium: Experiences and Challenges From Southern India**
Subramanian Senthilkumaran, Ramachandran Meenakshisundaram, Wedatallah Osman, and Ponniah Thirumalaikolundusubramanian
- 919** **In Reply—Acute Myocardial Infarction During Pregnancy and the Puerperium: Experiences and Challenges From Southern India**
Nathaniel R. Smilowitz and Harmony R. Reynolds
- 920** **The Importance of Educational Interventions and Regional Analgesia in Tackling the Opioid Crisis in the United States**
Hytham K.S. Hamid
- 921** **In Reply—The Importance of Educational Interventions and Regional Analgesia in Tackling the Opioid Crisis in the United States**
Matthew J. Ziegelmann, Elizabeth B. Habermann, and Matthew T. Gettman

Medical Images

- 923** **Foreign Body Impaction in the Esophagus**
Masayuki Shibata and Tateaki Naito
- 924** **Erdheim-Chester Disease**
Alexander Poellinger and Jons Hrycyk

Path to Patient Image Quiz

- 926** **Splenic Hemangioma**
Lori A. Erickson

Stamp Vignette on Medical Science

- e67** **Andreas Vesalius and *De Fabrica***
Ahmadreza Afshar, David P. Steensma, and Robert A. Kyle

Art at Mayo Clinic

e69 *Nuestro Senor de los Temblores* by Anonymous
Margaret R. Wentz

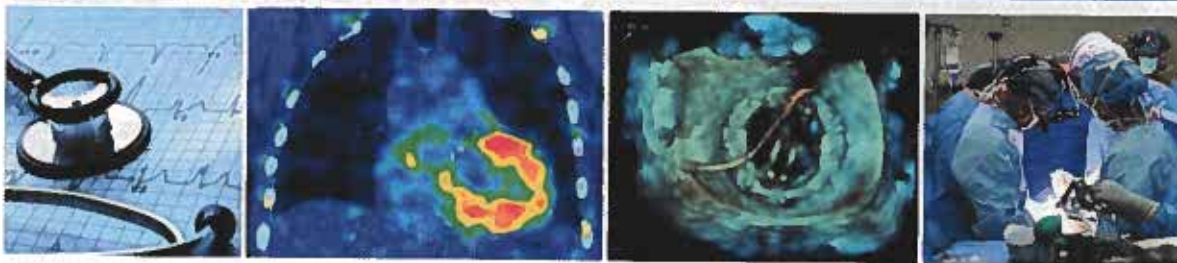
Other Features

33A Professional Opportunities

Coming Soon...

- | | |
|----------------------------------------------------------------------------------|---------------------------------------------------------------------------------|
| Effectiveness of Cancer Screening | Functional Disability in Rheumatoid Arthritis |
| Diagnostic Accuracy in Primary Care E-Visits | Thyrotoxicosis: Diagnosis and Management |
| Antimicrobial Resistance: Practical Interventions | Brain MRI Findings in Infective Endocarditis |
| Relevance of Physical Fitness and Adiposity on Life Expectancy | Wernicke Encephalopathy |
| What to Offer Patients With Severe Obesity Who Do Not Undergo Bariatric Surgery? | Hereditary Breast-Ovarian Cancer Syndromes |
| Hospital Charges for Urologic Surgery | Hereditary Gastrointestinal Cancer Syndromes |
| Renal Infarction and Renal Function in Patients With Cardiac Amyloidosis | Oral Anticoagulation for Stroke Prevention in Patients With Atrial Fibrillation |
| | Renal Replacement Therapy After Left Ventricular Assist Device Implantation |

Cover Image



The cover image features a cardiovascular theme. The outer left panel displays the stethoscope, the time-honored instrument for listening; this symbolizes individualized care that listens and responds to the patient. Cardiac evaluation may involve a noninvasive office test, the ECG, and, where indicated, noninvasive imaging, in this case, a SPECT CT of the heart (left-of-center) showing increased uptake of technetium pyrophosphate in diagnosing wild-type transthyretin cardiac amyloidosis. The right-of-center panel is from a 3D echocardiogram, left atrium-view of a mechanical mitral bileaflet prosthesis sewing ring and prosthesis leaflets during percutaneous transcatheter closure of a perivalvular leak. A guide wire hovers over the prosthesis, and the imager is guiding the interventional cardiologist to position the tip of the guide wire through one of the perivalvular leak sites. The outer right panel depicts a surgical team involved in cardiac surgery and underscores the importance of teamwork.

Continued

