



MAYO CLINIC PROCEEDINGS

www.mayoclinicproceedings.org



Table of Contents

March 2019 Volume 94 Number 3

The April online issue of *Proceedings* will be available by Monday, April 1.
Sign up for an alert to the online Table of Contents at www.mayoclinicproceedings.org

Editorials



- 375 Robert A. Kyle, MD: Lessons From a Legend**
S. Vincent Rajkumar
- 377 Hospitalization Is an Underutilized Opportunity to Vaccinate for Influenza**
Evan J. Anderson, Carol Kao, and Inci Yildirim
- 380 White Matter Hyperintensities on Magnetic Resonance Imaging: What Is a Clinician to Do?**
José G. Merino
- 383 Global Village, International Travel, and Risk of Communicable Disease**
Priya Sampathkumar and Karl A. Nath
- 385 Yoga: Safe for All?**
Raza Awan and Edward R. Laskowski
- 388 New Insights Into a Multifaceted Disease**
Mario Nuvolone and Giampaolo Merlini
- 391 Progress in Drug Discovery in Academia and Persistent Challenges of “the Valley of Death”**
Richard J. Barohn, Scott J. Weir, and Robert D. Simari



Commentary

- 394 A 50-Year-Long Study of Waldenström Macroglobulinemia**
Efstathios Kastiris and Meletios A. Dimopoulos

Original Articles



- 397 Safety of Influenza Vaccination Administered During Hospitalization**
Sara Y. Tartof, Lei Qian, In-Lu Amy Liu, Hung Fu Tseng, Lina S. Sy, Rulin C. Hechter, Bruno J. Lewin, and Steven J. Jacobsen  
- These findings provide reassurance about the safety of influenza vaccination during hospitalization. Every contact with a health care professional, including during a hospitalization, is an opportunity to vaccinate.

Continued

- 408 Severity of White Matter Hyperintensities and Effects on All-Cause Mortality in the Mayo Clinic Florida Familial Cerebrovascular Diseases Registry**
Tasneem F. Hasan, Kevin M. Barrett, Thomas G. Brott, Mohammed K. Badi, Elizabeth R. Lesser, David O. Hodge, and James F. Meschia 
 An increasing burden of cerebral small-vessel disease, as characterized by white matter hyperintensities, is associated with increased risk of all-cause mortality.
- 417 Leprosy in a Midwestern Dermatology Clinic: Report of 9 Patients**
Spencer A. Bezael, Oluwakemi Onajin, Tania M. Gonzalez-Santiago, Robin Patel, Bobbi S. Pritt, Abinash Virk, Lawrence E. Gibson, and Margot S. Peters
 Leprosy should be considered in the differential diagnosis when evaluating both foreign- and US-born patients with granulomatous dermatitis and peripheral neuropathy.
- 424 Soft Tissue and Bony Injuries Attributed to the Practice of Yoga: A Biomechanical Analysis and Implications for Management**
Melody Lee, Elizabeth A. Huntoon, and Mehrsheed Sinaki 
 Yoga potentially has many health benefits, but it is not without risk. Patients with osteopenia or osteoporosis may benefit from avoiding extreme spinal flexion.
- 432 Yoga as Antihypertensive Lifestyle Therapy: A Systematic Review and Meta-analysis**
Yin Wu, Blair T. Johnson, Rebecca L. Acabchuk, Shiqi Chen, Holly K. Lewis, Jill Livingston, Crystal L. Park, and Linda S. Pescatello 
 Yoga is a viable antihypertensive lifestyle therapy that produces the greatest blood pressure benefits when breathing techniques and meditation/mental relaxation are included.
- 447 Utility of the Serum Free Light Chain Assay in the Diagnosis of Light Chain Amyloidosis in Patients With Heart Failure**
Ian C. Chang, Angela Dispenziera, Christopher G. Scott, Grace Lin, Allan S. Jaffe, Kyle W. Klarich, and Martha Grogan 
 A targeted approach of the serum free light chain assay may lead to an earlier diagnosis and treatment of light chain amyloidosis, with the potential to improve outcomes in an era of expanding therapies.
- 455 Prognostic Significance of Holter Monitor Findings in Patients With Light Chain Amyloidosis**
Surbhi Sidana, Nidhi Tandon, Peter A. Brady, Martha Grogan, Morie A. Gertz, Angela Dispenziera, Grace Lin, David Dingli, Francis K. Buadi, Martha Q. Lacy, Prashant Kapoor, Wilson I. Gonsalves, Eli Muchtar, Rahma Warsame, Shaji K. Kumar, and Taxiarchis V. Kourelis
 Atrial fibrillation and nonsustained ventricular tachycardia on 24-hour Holter monitoring do not impact peritransplant mortality but are associated with inferior short-term overall survival outcomes.
- 465 Incidence of AL Amyloidosis in Olmsted County, Minnesota, 1990 through 2015**
Robert A. Kyle, Dirk R. Larson, Paul J. Kurtin, Shaji Kumar, James R. Cerhan, Terry M. Thorneau, S. Vincent Rajkumar, Celine M. Vachon, and Angela Dispenziera
 The incidence of immunoglobulin light chain amyloidosis in Olmsted County has not changed significantly in the past 66 years.
- 472 A Modern Primer on Light Chain Amyloidosis in 592 Patients With Mass Spectrometry-Verified Typing**
Eli Muchtar, Morie A. Gertz, Robert A. Kyle, Martha Q. Lacy, David Dingli, Nelson Leung, Francis K. Buadi, Suzanne R. Hayman, Prashant Kapoor, Yi Lisa Hwa, Amie Fonder, Minam Hobbs, Wilson Gonsalves, Taxiarchis V. Kourelis, Rahma Warsame, Stephen Russell, John A. Lust, Yi Lin, Ronald S. Go, Steven Zeldenzust, S. Vincent Rajkumar, Shaji K. Kumar, and Angela Dispenziera 
 This article represents a comprehensive review of the presentation and outcomes of light chain amyloidosis verified by accurate typing using mass spectrometry.


Brief Report

484 Premedication With Gabapentin Significantly Reduces the Risk of Postherpetic Neuralgia in Patients With Neuropathy

Shirin Ghanavatan, Christopher S. Wie, Rhonda S. Low, Nan Zhang, Jordan M. Montoya, Gurman Singh Dhaliwal, and David L. Swanson  



Special Article

490 Translation to Practice: Accelerating the Cycle of Innovation to Impact

Jeff R. Anderson, Thomas D.Y. Chung, Leon Clark, Jennifer A. Weis, Andrew J. Danielsen, Sundeep Khosla, Gregory J. Gores, and Andrew D. Badley 

Review

500 Prediction of the Renal Elimination of Drugs With Cystatin C vs Creatinine: A Systematic Review

Erin F. Barreto, Andrew D. Rule, M. Hassan Murad, Kianoush B. Kashani, John C. Lieske, Patricia J. Erwin, James M. Steckelberg, Ognjen Gajic, Joel M. Reid, and Sandra L. Kane-Gill  

Concise Review for Clinicians—CME Credit Offered

515 Institutional Review Boards: What Clinician Researchers Need to Know

Maria I. Lapid, Bart L. Clarke, and R. Scott Wright

Please note that articles with an "e" page designation are available only in the online version of the Journal at www.mayoclinicproceedings.org

Residents' Clinic


526 58-Year-Old Diabetic Man With a Warm, Erythematous Foot

Alexandra Higgins, Miguel Teixeira, and Jason H. Szostek

531 48-Year-Old Man With Bilateral Mediastinal Lymphadenopathy, Orbital Pseudotumors, Kidney Masses, and Acute Pancreatitis

Hasan Ahmad Hasan Albitar and Eva M. Carmona

e39 65-Year-Old Woman With a Wheeze

Divya Padmanabhan Menon and Neal M. Patel 

Thematic Review Series on Women's Health—CME Credit Offered


536 Androgens and Blood Pressure Control: Sex Differences and Mechanisms

Jane F. Reckelhoff

Letters to the Editor

- 544** **Mona Lisa and Postpartum Hypothyroidism**
Antonio Ponzetto, Natale Figura, and John Holton
- 544** **In reply—Mona Lisa and Postpartum Hypothyroidism**
Mandeep R. Mehra
- 545** **Is There an “Asymptote of Gain” Beyond Which Further Increases in Cardiorespiratory Fitness Convey No Additional Benefits on Mortality and Atrial Fibrillation?**
Sae Young Jae, Sudhir Kurl, Hyun Jeong Kim, Barry A. Franklin, Setor K. Kunutsor, Mira Kang, and Jari A. Laukkanen
- 547** **Neither Here nor There: Intracardiac Thrombus in Transit Wedged in a Patent Foramen Ovale**
Michel T. Corban, Omar W.J. Alothman, William P. Martin, Thomas C. Gerber, Ana I. Casanegra, Jae K. Oh, and Guy S. Reeder
- 549** **Burnout Among Physicians Compared With Individuals With a Professional or Doctoral Degree in a Field Outside of Medicine**
Tait D. Shanafelt, Christine Sinsky, Lotte N. Dyrbye, Mickey Trockel, and Colin P. West
- 551** **Methamphetamine-Associated Cardiomyopathy in Pregnancy: A Case Series**
Stephanie L. Pierce, Emily W. Zantow, Sabrina D. Phillips, and Marvin Williams

Medical Images

- 555** **Postoperative Trouble**
Madiha Fida and Omar Abu Saleh
- 557** **Exfoliative Esophagitis Induced By Sunitinib**
Kazuyoshi Nagata and Yuko Akazawa 

Path to Patient Image Quiz

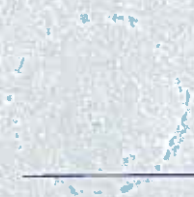- 559** **Posterior Mediastinal Schwannoma (Neurilemmoma)**
Lori A. Erickson

Stamp Vignette On Medical Science

- e45** **John Shaw Billings: Civil War Surgeon, Medical Librarian, Founder of *Index Medicus*, and First Director of the New York Public Library**
Robert A. Kyle and David P. Steensma 

Art at Mayo Clinic

- e47** **Joy by Anne Moran and Robert A. Brown**
Margaret R. Wentz 



Other Features

- 21A Professional Opportunities
554 Correction

Coming Soon...

How Low to Go With Lipid Lowering Therapies

Conversation Aid for Shared Decision Making in Anticoagulation Choice

Upper Gastrointestinal Bleeding: Etiologies and Management

Portal Hypertension and Related Complications

Ethical Considerations in Withdrawing Extracorporeal Membrane Oxygenation Support

Peer-Review Bias: A Critical Review

Finding Hope and Healing When Cure is Not Possible

Elements of a Work Life Balance Plan - Another Form of Individualized Medicine

Fluoroscopically Guided vs Landmark-Guided Sacroiliac Joint Injections

Muscular Strength and Incidence of Type 2 Diabetes

Gender Disparities in Bystander Cardiopulmonary Resuscitation

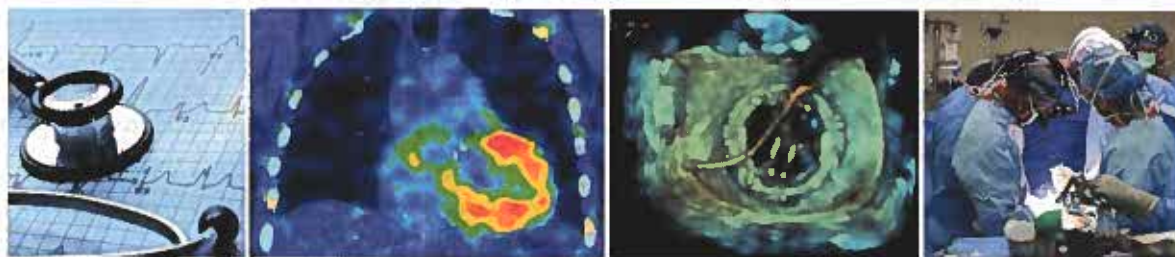
Hospital Admissions After Cardiac Implantable Electronic Device Procedures

Patients With Myeloproliferative Neoplasms

Distinct Uric Acid Trajectories and Risk of Incident Hypertension

Circulating Osteogenic Progenitor Cells in Aortic Valve Stenosis

Cover Image



The cover image features a cardiovascular theme. The outer left panel displays the stethoscope, the time-honored instrument for listening; this symbolizes individualized care that listens and responds to the patient. Cardiac evaluation may involve a noninvasive office test, the ECG, and, where indicated, noninvasive imaging, in this case, a SPECT CT of the heart (left-of-center) showing increased uptake of technetium pyrophosphate in diagnosing wild-type transthyretin cardiac amyloidosis. The right-of-center panel is from a 3D echocardiogram, left atrium-view of a mechanical mitral bileaflet prosthesis sewing ring and prosthesis leaflets during percutaneous transcatheter closure of a perivalvular leak. A guide wire hovers over the prosthesis, and the imager is guiding the interventional cardiologist to position the tip of the guide wire through one of the perivalvular leak sites. The outer right panel depicts a surgical team involved in cardiac surgery and underscores the importance of teamwork.



Continued