



MAYO CLINIC PROCEEDINGS

www.mayoclinicproceedings.org



Table of Contents



January 2019 Volume 94 Number 1

The February online issue of *Proceedings* will be available by Friday, February 1.
Sign up for an alert to the online Table of Contents at www.mayoclinicproceedings.org

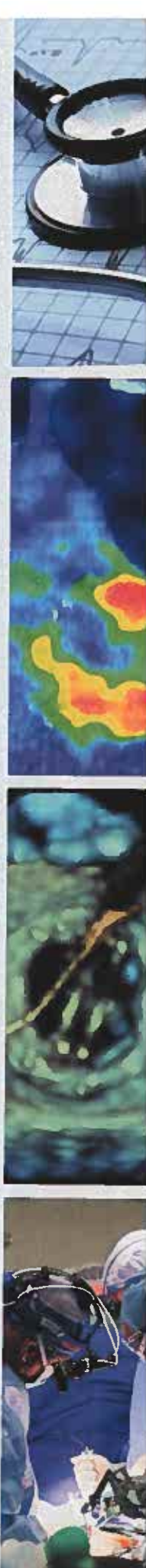
Editorials

- 1 **Navigating the Muddy Waters of Vancomycin Nephrotoxicity**
Erin F. Barreto, Jason N. Barreto, and Andrew D. Rule
- 4 **A New Fix for the Bishop's Hat, Let's Give It Time to Wear Before We Pass Judgment**
Joseph G. Murphy, Sushil Allen Luis, and R. Scott Wright
- 7 **Genomics as a Scientifically Based Fortune-teller**
Dusica Babovic-Vuksanovic
- 10 **Threading the Needle: Individualized Monitoring Guides the Transition From Cytomegalovirus Prophylaxis to Primary Immune Response in a Face Transplant Recipient**
Matthew D. Griffin
- 13 **A Bicentennial, a Centennial, and *Mayo Clinic Proceedings***
Karl A. Nath

Original Articles

- 17 **Elevated Vancomycin Trough Levels in a Tertiary Health System: Frequency, Risk Factors, and Prognosis**
Reza Zonozi, Aozhou Wu, Jung-Im Shin, Alex Secora, Josef Coresh, Lesley A. Inker, Alex R. Chang, and Morgan E. Grams 
Careful use and monitoring of vancomycin therapy, particularly in overweight/obese patients or those with chronic kidney disease, may substantially reduce in-hospital morbidity.
- 27 **Large Chromosomal Rearrangements Yield Biomarkers to Distinguish Low-Risk From Intermediate- and High-Risk Prostate Cancer**
George Vasmatzis, Farhad Kosari, Stephen J. Murphy, Simone Terra, Irina V. Kovtun, Faye R. Harris, Shabnam Zarei, James B. Smadbeck, Sarah H. Johnson, Athanasios G. Gaitatzes, Terry M. Themeau, Laureano J. Rangel, Ryan A. Knudson, Patricia Greipp, William R. Sukov, Darlene L. Knutson, Sara M. Kloft-Nelson, R. Jeffrey Kames, and John C. Cheville 
Assays based on these probes hold promise for the risk evaluation of men with GS6 in the prostate needle biopsy specimen.

Continued



- 37** **Low Rate of Intrahospital Deep Venous Thrombosis in Acutely Ill Medical Patients: Results From the AURELIO Study**
Lorenzo Loffredo, Vincenzo Arienti, Gianpaolo Vidili, Chiara Cogliati, Simona Battaglia, Ludovica Perri, Rosella Di Giulio, Scaila Bernardini, Maria Luna Summa, Angela Sciacqua, Francesco Perticone, Maria Boddi, Giovanni Di Minno, Corrado Lodigiani, Antonello Pietrangelo, Alessio Farcomeni, and Francesco Violi; AURELIO Study Group 🇮🇹
- This study found that in acutely ill medical patients almost all proximal deep venous thromboses were already detectable at admission, whereas deep venous thrombosis incidence during hospitalization was negligible.
- 44** **Socioeconomic Status, Race/Ethnicity, and Health Disparities in Children and Adolescents in a Mixed Rural-Urban Community—Olmsted County, Minnesota**
Kara A. Bjur, Chung-II Wi, Euijung Ryu, Chris Derauf, Sheri S. Crow, Katherine S. King, and Young J. Juhn
- Major health disparities are present in both clinically more and less overt health outcomes across socioeconomic status and race/ethnicity in children living in a mixed rural-urban community.
- 54** **Electroacupuncture Versus Pelvic Floor Muscle Training Plus Solifenacin for Women With Mixed Urinary Incontinence: A Randomized Noninferiority Trial**
Baoyan Liu, Yan Liu, Zongshi Qin, Kehua Zhou, Huangfang Xu, Liyun He, Ning Li, Tongsheng Su, Jianhua Su, Zenghui Yue, Zhiwei Zang, Wei Zhang, Jiping Zhao, Zhongyu Zhou, Lian Liu, Dongning Wu, Jiani Wu, Jing Zhang, Ran Pang, Yang Wang, Jia Liu, Jinna Yu, and Zhishun Liu 🇨🇳
- In women with moderate to severe mixed urinary incontinence, electroacupuncture shows promise as an effective treatment alternative.
- 66** **Septal Myectomy in Hypertrophic Cardiomyopathy: National Outcomes of Concomitant Mitral Surgery**
Kimberly A. Holst, Kristine T. Hanson, Steve R. Ommen, Rick A. Nishimura, Elizabeth B. Habermann, and Hartzell V. Schaff 🇺🇸 🇮🇹 🇨🇳
- The addition of mitral valve replacement and other concomitant cardiac procedures was associated with increased rates of hospital mortality and length of stay compared with patients undergoing isolated septal myectomy.
- 74** **Postmarketing Safety-Related Modifications of Drugs Approved by the US Food and Drug Administration Between 1999 and 2014 Without Randomized Controlled Trials**
Daniel Shepshelovich, Ariadna Tibau, Hadar Goldvaser, Alberto Ocana, Bostjan Seruga, and Eitan Amir 🇮🇸 🇮🇹 🇨🇳
- FDA approval of drugs without supporting randomized controlled trials can expedite patient access to effective new treatments, but health care professionals prescribing these drugs should be vigilant for unrecognized adverse effects.

Brief Report

- 84** **Cost Efficacy of α -Galactosidase A Enzyme Screening for Fabry Disease**
Darrell B. Newman, William R. Miranda, Dietrich Matern, Dawn S. Peck, Jeffrey B. Geske, Joseph J. Maleszewski, Steve R. Ommen, and Michael J. Ackerman

Special Articles

- 89** **Percutaneous Transcatheter Edge-to-Edge MitraClip Technique: A Practical “Step-by-Step” 3-Dimensional Transesophageal Echocardiography Guide**
Limor Ilan Bushari, Guy S. Reeder, Mackram F. Eleid, Krishnaswamy Chandrasekaran, Maurice Enriquez-Sarona, Charanjit S. Rihal, and Joseph F. Malouf 🇮🇹 🇨🇳

103 Reconciling Opportunistic and Population Screening in Clinical Genomics

Kyle B. Brothers, Jason L. Vassy, and Robert C. Green

Reviews

110 Exceptional Human Longevity

Robert J. Pignolo

125 Echocardiographic Assessment of Left Ventricular Systolic Function: An Overview of Contemporary Techniques, Including Speckle-Tracking Echocardiography

Sushil A. Luis, Jonathan Chan, and Patricia A. Pellikka

Concise Review for Clinicians—CME Credit Offered

139 Chronic Abdominal Wall Pain: A Common Yet Overlooked Etiology of Chronic Abdominal Pain

Amrit K. Kamboj, Patrick Hoversten, and Amy S. Oxentenko 

Please note that articles with an "e" page designation are available only in the online version of the Journal at www.mayoclinicproceedings.org

Residents' Clinic

145 57-Year-Old Woman With Fever and Confusion

C.-Y. (Joy) Chen and Abinash Virk

149 69-Year-Old Woman With Fatigue, Dyspnea, and Lower Extremity Pain

Paul V. Viscuse and Arya B. Mohabbat

e1 40-Year-Old Man With Fatigue, Dyspnea, and Nausea

Jaime de la Fuente, S. Bradley Hicks, and Nandan S. Anavekar 

Thematic Review Series on Gastroenterological Diseases—CME Credit Offered

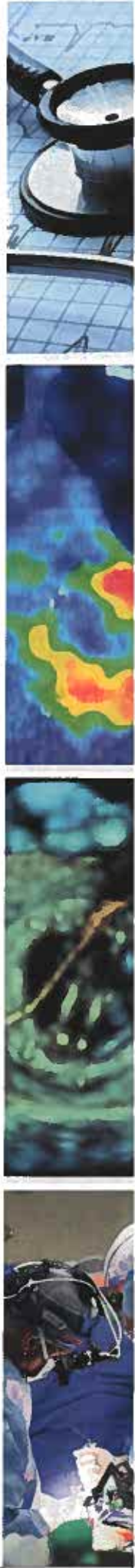
155 Mechanisms of Disease: Inflammatory Bowel Diseases

Guilherme Piovezani Ramos and Konstantinos A. Papadakis 

Case Report

166 Application of a New Paradigm for Cytomegalovirus Disease Prevention in Mayo Clinic's First Face Transplant

Raymund R. Razonable, Hatem Amer, and Samir Mardini 



Letters to the Editor


171 Ethanol Ablation of Cystic Thyroid Nodules

Teck K. Khoo

171 In Reply—Ethanol Ablation of Cystic Thyroid Nodules

M. Regina Castro, Nicole M. Iniguez-Ariza, Robert A. Lee, Naykky M. Singh-Ospina, and Manus N. Stan

Medical Images

172 Multiple Erythema Migrans Rashes Characteristic of Early Disseminated Lyme Disease, Before and After TherapyAditya S. Shah and Bharath Raj Varatharaj Palraj **174 Recurrent Erythema Nodosum as a Warning of Tuberculous Lymphadenitis**

Tatsuya Fujikawa and Akemi Senoo

Path to Patient Image Quiz


176 Lipoma

Lori A. Erickson

STAMP VIGNETTE ON MEDICAL SCIENCE

e7 Georges de Bellio (1826–1894): Doctor, Friend, and Patron of the Impressionist PaintersDan L. Dumitrascu, Robert A. Kyle, and David P. Steensma 

Art at Mayo Clinic

e9 Celebration, Mexican Lily, and Sayolita Life by Paul Alan BennettMargaret R. Wentz 

Other Features

25A Professional Opportunities

Coming Soon...

Excessive Generic Drug Prices in the American Health Care System

Predictors of Symptomatic Kidney Stone Recurrence

Cardiovascular Disease in Type 2 Diabetes

Pulmonary Manifestations in Connective Tissue Diseases

Coaching Patients Living With Multimorbidity

Exercise and Pharmacological Interventions on Visceral Adiposity

Body Mass Index and Atrial Fibrillation

Factors Associated With Meningioma

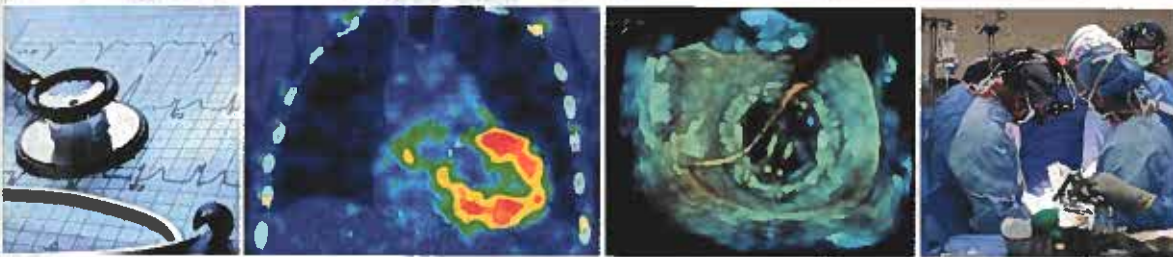
Postoperative Urologic Surgery Opioid Prescribing

Amantadine Use for Post-Concussion Syndrome

Abdominal Wall Pain: A Common Clinical Problem

EXIT Procedure for a Fetus With Hypoplastic Left Heart Syndrome

Cover Image



The cover image features a cardiovascular theme. The outer left panel displays the stethoscope, the time-honored instrument for listening; this symbolizes individualized care that listens and responds to the patient. Cardiac evaluation may involve a noninvasive office test, the ECG, and, where indicated, noninvasive imaging, in this case, a SPECT CT of the heart (left-of-center) showing increased uptake of technetium pyrophosphate in diagnosing wild-type transthyretin cardiac amyloidosis. The right-of-center panel is from a 3D echocardiogram, left atrium-view of a mechanical mitral bileaflet prosthesis sewing ring and prosthesis leaflets during percutaneous transcatheter closure of a perivalvular leak. A guide wire hovers over the prosthesis, and the imager is guiding the interventional cardiologist to position the tip of the guide wire through one of the perivalvular leak sites. The outer right panel depicts a surgical team involved in cardiac surgery and underscores the importance of teamwork.

