

ISSUE @ A GLANCE

-  **Managing stable coronary artery disease: drugs, PCI, or devices**
T.F. Lüscher 901

CardioPulse

- Andreas Zeiher MD**
M. Nicholls 905
- ESC Gold Medallists 2017**
A. Tofteld 907
- Hypertension Guidelines**
M. Burnier 908
- Innovations in Medicine and Cost Savings: An Impossible Equation?**
N. Martelli, K. Narayanan, and M. Eloi 911
- Nuclear Cardiology**
A.P. Pazhenkottil 913

CURRENT OPINION

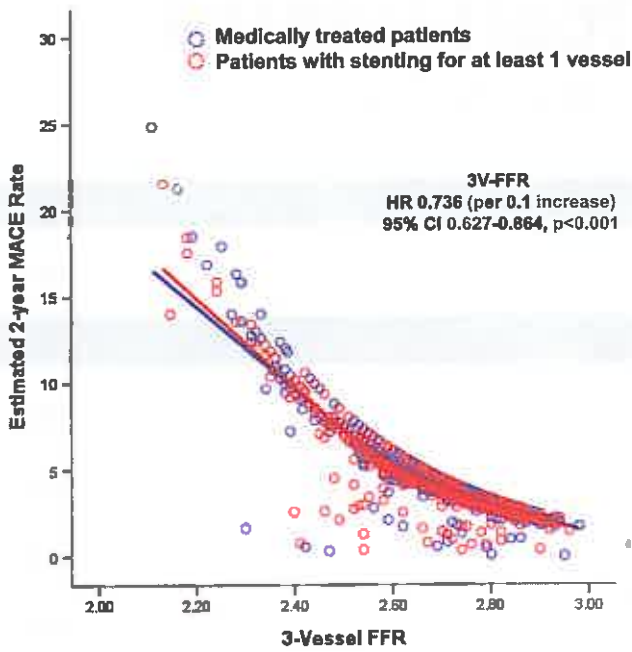
- Clinical update**
The Year in Cardiology 2017: Coronary Interventions
S.D. Kristensen, M. Maeng, D. Capodanno, and W. Wijns 914

REVIEW

- Coronary artery disease**
The Reducer device in patients with angina pectoris: mechanisms, indications, and perspectives
M. Königstein, F. Giannini, and S. Banai 925

CLINICAL RESEARCH

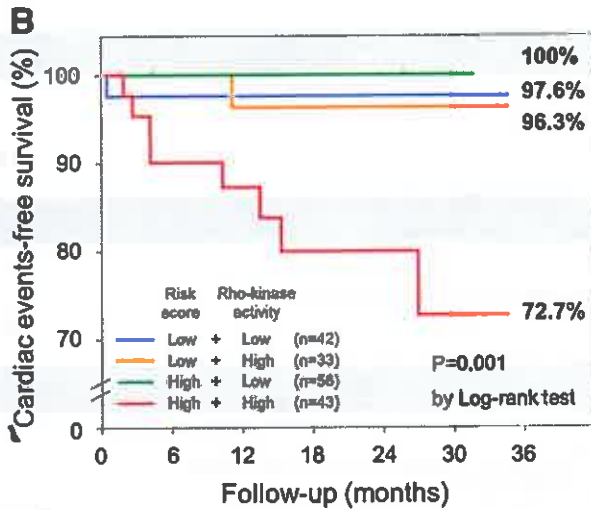
- Coronary artery disease**
Prognostic value of coronary computed tomographic angiography findings in asymptomatic individuals: a 6-year follow-up from the prospective multicentre international CONFIRM study
I. Cho, S.J. Al'Aref, A. Berger, B. Ó Hartaigh, H. Gransar, V. Valenti, F.Y. Lin, S. Achenbach, D.S. Berman, M.J. Budoff, T.Q. Callister, M.H. Al-Mallah, F. Cademartiri, K. Chinnaiyan, B.J.W. Chow, A. DeLago, T.C. Villines, M. Hadamitzky, J. Hausleiter, J. Leipsic, L.J. Shaw, P.A. Kaufmann, G. Feuchtner, Y.-J. Kim, E. Maffei, G. Raff, G. Pontone, D. Andreini, H. Marques, R. Rubinshtein, H.-J. Chang, and J.K. Min 934
- Editorial**
Risk prediction by non-invasive coronary imaging: we are not there yet!
M. Joner and W. Koenig 942



Clinical implications of three-vessel fractional flow reserve measurement in patients with coronary artery disease

J.M. Lee, B.-K. Koo, E.-S. Shin, C.-W. Nam, J.-H. Doh, D. Hwang, J. Park, K.-J. Kim, J. Zhang, X. Hu, J. Wang, C. Ahn, F. Ye, S. Chen, J. Yang, J. Chen, N. Tanaka, H. Yokoi, H. Matsuo, H. Takashima, Y. Shiono, and T. Akasaka

945



Prognostic impacts of Rho-kinase activity in circulating leucocytes in patients with vasospastic angina

T. Nihei, J. Takahashi, K. Hao, Y. Kikuchi, Y. Odaka, R. Tsuburaya, K. Nishimiya, Y. Matsumoto, K. Ito, S. Miyata, Y. Sakata, and H. Shimokawa

952

No. at risk

Low + Low	42	38	27	20	15	7
Low + High	33	29	25	17	13	5
High + Low	56	44	34	20	7	3
High + High	43	34	27	17	12	7

Editorial

The Rho(ad)-kinase for individualized treatment of vasospastic angina

R.J. Widmer, L.O. Lerman, and A. Lerman

960

VIEW POINT

Coronary artery disease

ORBITA revisited: what it really means and what it does not?

B.R. Chaitman, M. Mori Brooks, K. Fox, and T.F. Lüscher

963

CARDIOVASCULAR FLASHLIGHT

Seeing the unseen: post-infarction inflammation in an isolated right ventricular myocardial infarction visualized by combined cardiac magnetic resonance imaging and chemokine receptor CXCR4-targeted molecular imaging

T. Koenig, D.G. Sedding, H.-J. Wester, and T. Derlin

966

CORRIGENDUM

Corrigendum to: Cardiovascular safety of non-aspirin non-steroidal anti-inflammatory drugs: review and position paper by the working group for Cardiovascular Pharmacotherapy of the European Society of Cardiology

924

ERRATUM

Erratum to: Heme oxygenase-1 suppresses a pro-inflammatory phenotype in monocytes and determines endothelial function and arterial hypertension in mice and humans

967

 For the podcast associated with this article, please visit <https://academic.oup.com/eurheartj/pages/Podcasts>



Visit EIJ's mobile site
<https://academic.oup.com/eurheartj>



www.eurheartj.org