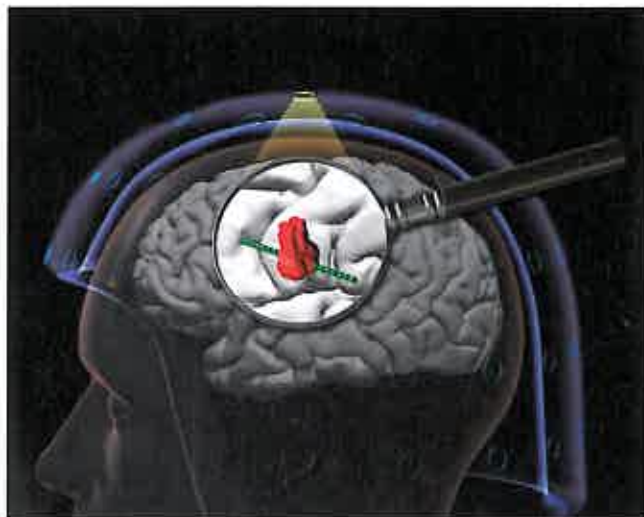


# BRAIN

A JOURNAL OF NEUROLOGY



**Cover image:** The global view afforded by MEG can help target placement of stereo-electroencephalography electrodes to the relevant brain region, allowing more accurate sampling and visualization of the electrically abnormal cortex by depth recordings. From Murakami *et al.* Correlating magnetoencephalography to stereo-electroencephalography in patients undergoing epilepsy surgery. Pp. 2935–2947.

## Contents

### Editorial

D. M. Kullmann  
2815

### Scientific Commentaries

**Retinal glymphatic system: an explanation for transient retinal layer volume changes?**

A. Petzold  
2816

**Defining retinal vasculopathy with cerebral leukoencephalopathy and systemic manifestations**

A. Charidimou  
2819

**Concordance between interictal MEG and stereo-EEG predicts seizure freedom after epilepsy surgery**

J. Bear and H. Kirsch  
2821

**Why the left posterior inferior temporal lobe is needed for word finding**

T. M. H. Hope and C. J. Price  
2823

### Review Article

**Visual dysfunction in Parkinson's disease**

R. S. Weil, A. E. Schrag, J. D. Warren, S. J. Crutch, A. J. Lees and H. R. Morris  
2827

### Reports

**Advantages and pitfalls of an extended gene panel for investigating complex neurometabolic phenotypes**

E. S. Reid, A. Papandreou, S. Drury, C. Boustred, W. W. Yue, Y. Wedatilake, C. Beesley, T. S. Jacques, G. Anderson, L. Abulhoul, A. Broomfield, M. Cleary, S. Grunewald, S. M. Varadkar, N. Lench, S. Rahman, P. Gissen, P. T. Clayton and P. B. Mills  
2844

**Retinal inner nuclear layer volume reflects response to immunotherapy in multiple sclerosis**  
B. Knier, P. Schmidt, L. Aly, D. Buck, A. Berthele, M. Mühlau, C. Zimmer, B. Hemmer and T. Korn  
2855

### Original Articles

**The metabolomic signature of Leber's hereditary optic neuropathy reveals endoplasmic reticulum stress**  
J. M. Chao de la Barca, G. Simard, P. Amati-Bonneau, Z. Safiedeen, D. Prunier-Mirebeau, S. Chupin, C. Gadras, L. Tessier, N. Gueguen, A. Chevrollier, V. Desquière-Dumas, M. Ferré, C. Bris, J. Kouassi Nzoughet, C. Bocca, S. Leruez, C. Verny, D. Miléa, D. Bonneau, G. Lenaers, M. Carmen Martinez, V. Procaccio and P. Reynier  
2864

**Loss of function of SLC25A46 causes lethal congenital pontocerebellar hypoplasia**  
J. Wan, J. Steffen, M. Yourshaw, H. Mamsa, E. Andersen, S. Rudnik-Schöneborn, K. Pope, K. B. Howell, C. A. McLean, A. J. Kornberg, J. Joseph, P. J. Lockhart, K. Zerres, M. M. Ryan, S. F. Nelson, C. M. Koehler and J. C. Jen  
2877

**Unbiased screen identifies aripiprazole as a modulator of abundance of the polyglutamine disease protein, ataxin-3**  
M. d. C. Costa, N. S. Ashraf, S. Fischer, Y. Yang, E. Schapka, G. Joshi, T. J. McQuade, R. M. Dharia, M. Dulchavsky, M. Ouyang, D. Cook, D. Sun, M. J. Larsen, J. E. Gestwicki, S. V. Todi, M. I. Ivanova and H. L. Paulson  
2891

**Retinal vasculopathy with cerebral leukoencephalopathy and systemic manifestations**  
A. H. Stam, P. H. Kothari, A. Shaikh, A. Gschwendter, J. C. Jen, S. Hodgkinson, T. A. Hardy, M. Hayes, P. A. Kempster, K. E. Kotschet, I. M. Bajema, S. G. van Duinen, M. L. C. Maat-Schieman, P. T. V. M. de Jong, M. D. de Smet, D. de Wolff-Rouendaal, G. Dijkman, N. Pelzer, G. R. Kolar, R. E. Schmidt, J. Lacey, D. Joseph, D. R. Fintak, M. G. Grand, E. M. Brunt, H. Liapis, R. A. Hajji-Ali, M. C. Kruit, M. A. van Buchem, M. Dichgans, R. R. Frants, A. M. J. M. van den Maagdenberg, J. Haan, R. W. Baloh, J. P. Atkinson, G. M. Terwindt and M. D. Ferrari  
2909

**CTLA4 blockade elicits paraneoplastic neurological disease in a mouse model**  
L. M. Yshii, C. M. Gebauer, B. Pignolet, E. Mauré, C. Quériault, M. Pierau, H. Saito, N. Suzuki, M. Brunner-Weinzierl, J. Bauer and R. Liblau  
2923

**Correlating magnetoencephalography to stereo-electroencephalography in patients undergoing epilepsy surgery**  
H. Murakami, Z. I. Wang, A. Marashly, B. Krishnan, R. A. Prayson, Y. Kakisaka, J. C. Mosher, J. Bulacio, J. A. Gonzalez-Martinez, W. E. Bingaman, I. M. Najm, R. C. Burgess and A. V. Alexopoulos  
2935

**Progressive gait ataxia following deep brain stimulation for essential tremor: adverse effect or lack of efficacy?**  
M. M. Reich, J. Brumberg, N. G. Pozzi, G. Marotta, J. Roothans, M. Åström, T. Musacchio, L. Lopiano, M. Lanotte, R. Lehrke, A. K. Buck, J. Volkmann and I. U. Isaias  
2948

**Vascular cognitive impairment neuropathology guidelines (VCING): the contribution of cerebrovascular pathology to cognitive impairment**  
O. A. Skrobot, J. Attems, M. Esiri, T. Hortobágyi, J. W. Ironside, R. N. Kalara, A. King, G. A. Lammie, D. Mann, J. Neal, Y. Ben-Shlomo, P. G. Kehoe and S. Love  
2957

**Intentional gaze shift to neglected space: a compensatory strategy during recovery after unilateral spatial neglect**  
Y. Takamura, M. Imanishi, M. Osaka, S. Ohmatsu, T. Tominaga, K. Yamanaka, S. Morioka and N. Kawashima  
2970

**TDP-43 stage, mixed pathologies, and clinical Alzheimer's-type dementia**  
B. D. James, R. S. Wilson, P. A. Boyle, J. Q. Trojanowski, D. A. Bennett and J. A. Schneider  
2983

**Variable disruption of a syntactic processing network in primary progressive aphasia**  
S. M. Wilson, A. T. DeMarco, M. L. Henry, B. Gesierich, M. Babiak, B. L. Miller and M. L. Gorno-Tempini  
2994

**Converging evidence for a cortico-subcortical network mediating lexical retrieval**  
G. Herbet, S. Moritz-Gasser, M. Boisseau, S. Duvaux, J. Cochereau and H. Duffau  
3007

**Your perspective and my benefit: multiple lesion models of self-other integration strategies during social bargaining**  
M. Melloni, P. Billeke, S. Baez, E. Hesse, L. de la Fuente, G. Forno, A. Birba, I. García-Cordero, C. Serrano, A. Plastino, A. Slachevsky, D. Huepe, M. Sigman, F. Manes, A. M. García, L. Sedeño and A. Ibáñez  
3022

### Dorsal column

#### Grey Matter

**Guillain-Barré syndrome in the 100 years since its description by Guillain, Barré and Strohl**  
R. A. C. Hughes, D. R. Cornblath and H. J. Willison  
3041

#### Book Review

**Brain network analysis: a practical tutorial**  
D. S. Bassett  
3048

Letters to the Editor

**Do we still need positron emission tomography for early Alzheimer's disease diagnosis?**

P. Lewczuk and J. Kornhuber

e60

**Reply: Do we still need positron emission tomography for early Alzheimer's disease diagnosis?**

S. Palmqvist, N. Mattsson and O. Hansson

e61

**The underestimated effect of normobaric hyperoxia on cerebral blood flow and its relationship to neuroprotection**

L. Chazalviel, H. N. David, B. Haelewyn, J.-E. Blatteau, N. Vallée, J.-J. Risso, S. Besnard and J. H. Abraini

e62

**Reply: The underestimated effect of normobaric hyperoxia on cerebral blood flow and its relationship to neuroprotection**

J.-C. Baron

e63

**ARID1B mutations are the major genetic cause of corpus callosum anomalies in patients with intellectual disability**

C. Mignot, M.-L. Moutard, A. Rastetter, L. Boutaud, S. Heide, T. Billette, D. Doummar, C. Garel, A. Afenjar, A. Jacquette, D. Lacombe, A. Verloes, C. Bole-Feysot, P. Nitschké, C. Masson, A. Faudet, F. Lesne, T. Bienvenu, C. Alby, T. Attié-Bitach, C. Depienne, C. Nava and D. Héron

e64

**Reply: ARID1B mutations are the major genetic cause of corpus callosum anomalies in patients with intellectual disability**

T. J. Edwards, E. H. Sherr, A. J. Barkovich and L. J. Richards

e65

**Corrigendum**

e66

